



# Perforation of the Esophagus (Boerhaave Syndrome): A Case Report

A. El Bakouri <sup>a</sup>, A. El Hayal <sup>a\*</sup>, S. El Kinani <sup>a</sup>, M. Bouali <sup>a</sup>,  
F. Z. Bensardi <sup>a</sup>, K. El Hattabi <sup>a</sup> and A. Fadil <sup>a</sup>

<sup>a</sup> *Faculté de Médecine et de Pharmacie de Casablanca, Hassan II University, Morocco.*

## **Authors' contributions**

*This work was carried out in collaboration among all authors. All authors read and approved the final manuscript.*

## **Article Information**

### **Open Peer Review History:**

This journal follows the Advanced Open Peer Review policy. Identity of the Reviewers, Editor(s) and additional Reviewers, peer review comments, different versions of the manuscript, comments of the editors, etc are available here: <https://www.sdiarticle5.com/review-history/98311>

**Case Study**

**Received: 03/02/2023**

**Accepted: 05/04/2023**

**Published: 08/04/2023**

## **ABSTRACT**

**Introduction:** Esophageal perforation represents one of the most serious and difficult emergencies that the surgeon may be confronted with. Most often, these are iatrogenic perforations, especially since the advent of endoscopic therapies. However, in about 15% of cases, as in the case of our patient, it is a Boerhaave syndrome. It is defined as a spontaneous rupture with no known pre-existing pathology of the esophagus. We report a case of Boerhaave syndrome treated surgically and review the characteristics and the treatment in the literature.

**Aim:** Our work is a retrospective case report with a descriptive aim concerning a patient operated for a perforation of the esophagus within the department of general surgery of CHU Ibn Rochd Casablanca.

**Case Report:** A 55-year-old man, chronic smoker at 35 pack years, presented to the department with left basio-thoracic pain evolving for 4 days, associated with early food vomiting, without any transit disorder or externalized digestive hemorrhage, all evolving in a context of fever and alteration of general condition. On physical examination, the patient was conscious and stable on the respiratory and hemodynamic level. Abdominal examination found tenderness in the left hypochondrium and left flank. The thoracic examination revealed a globular thorax, with decreased perception of vesicular murmurs and vocal vibrations. The thoracoabdominal CT scan (Fig. 1)

\*Corresponding author: E-mail: [a.elhayal@gmail.com](mailto:a.elhayal@gmail.com);

showed a bilateral pleural effusion, a pneumomediastinum and a left pneumothorax. It also showed digestive-like structures with air-fluid levels in the left hemithorax. The patient was rushed to the operating room. The operation consisted of a suture of a 5cm perforation of the abdominal esophagus by separate stitches with directed fistulization by Pezzer probe, with a feeding jejunostomy, a pre and retro esophageal drainage by 2 Delbet blades, a sub hepatic drainage by a Redon drain, a left phrenic drainage by a Joly drain, a biopsy of the perforation edges and a collection of the digestive fluid within the pleural cavity. The thoracic part of the operation consisted of an anterior thoracotomy through the 6th left intercostal space, which revealed the presence of digestive fluid within the pleural cavity, which was evacuated. Subsequently, an abundant saline lavage was performed with the placement of thoracic drains.

**Conclusion:** Boerhaave syndrome is one of the most serious emergencies. The prognosis depends greatly on early diagnosis and proper treatment. Surgery remains the gold standard of treatment.

*Keywords: Esophageal perforation; boerhaave syndrome; treatment; prognosis.*

## 1. INTRODUCTION

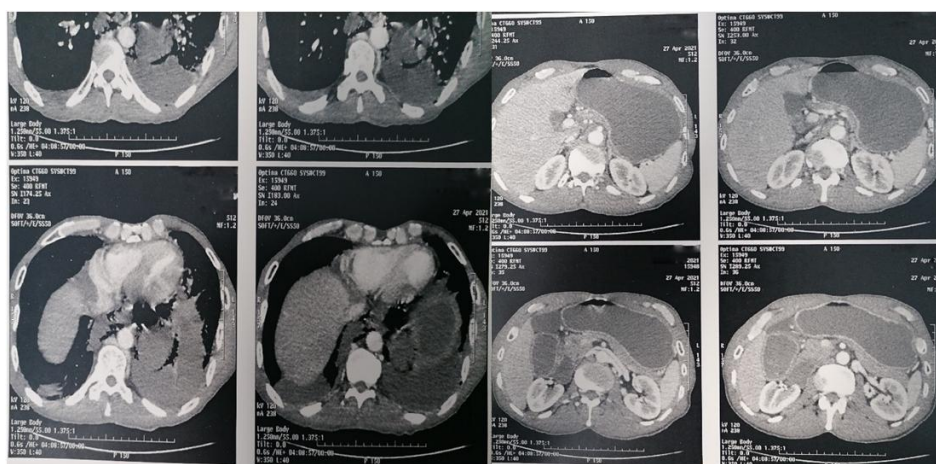
Esophageal perforation represents one of the most serious and difficult emergencies that the surgeon may be confronted with. It is defined by a tear or transmural rupture of the esophagus with contamination of surrounding spaces by salivary and gastric secretions and ingested food [1]. In the absence of adequate treatment, the infection sets in and rapidly becomes extensive with the appearance of septic shock. The mortality rate varies between 11.9% and 30% [1]. Most often, these perforations are iatrogenic, especially since the advent of endoscopic therapies. However, in about 15% of cases, as in the case of our patient, it is a Boerhaave syndrome, a spontaneous rupture with no known pre-existing pathology of the esophagus. It is mostly related to intense vomiting or severe retching, which probably causes an increase in intra-abdominal pressure. We report a case of Boerhaave syndrome treated surgically and review the characteristics and the treatment in the literature.

## 2. CASE REPORT

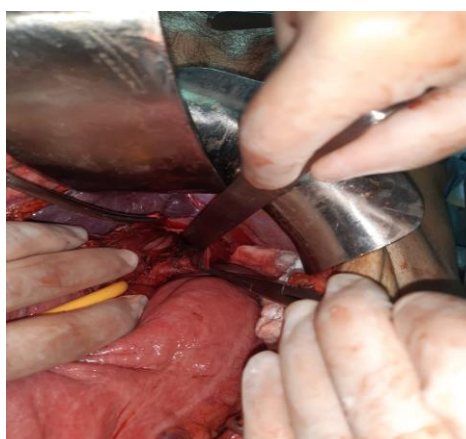
A 55-year-old man, chronic smoker at 35 pack years, presented to the department with left basithoracic pain evolving for 4 days, associated with early food vomiting, without any transit disorder or externalized digestive hemorrhage, all evolving in a context of fever and alteration of general condition. On physical examination, the patient was conscious and stable on the respiratory and hemodynamic level. Body temperature was at 37.8°C, blood pressure at 110/60 mmHg, respiratory rate at 24 breaths/min and heart rate at 100 beats/min. Abdominal

examination found tenderness in the left hypochondrium and left flank. The thoracic examination revealed a globular thorax, with decreased perception of vesicular murmurs and vocal vibrations. The thoracoabdominal CT scan (Fig. 1) showed a bilateral pleural effusion, of medium abundance on the left and of low abundance on the right, a pneumomediastinum of medium abundance and a left pneumothorax. It also showed digestive-like structures with air-fluid levels in the left hemithorax, with a doubt on a left diaphragmatic defect of 6.2mm, and a stasis stomach with duodenal dilatation at 43mm.

The patient was rushed to the operating room. On exploration, we found a stasis stomach, and a distension of the entire duodenal framework down to the 3rd jejunal loop, with no peritoneal effusion. The rest of the small intestine and colon were collapsed. The diaphragm was intact with ballooning of the left diaphragmatic dome (which was punctured bringing back digestive fluid). The abdominal esophagus was mobilized in relation to the phreno-esophageal membrane and the two pillars of the diaphragm, while respecting the 2 pneumogastric nerves. A lake was placed around the esophagus and dissected from the mediastinum, which resulted in the release of digestive fluid. A 5 cm esophageal perforation was found. The operation consisted of a suture of the perforation by separate stitches with directed fistulization by Pezzer probe, with a feeding jejunostomy, a pre and retro esophageal drainage by 2 Delbet blades, a sub hepatic drainage by a Redon drain, a left phrenic drainage by a Joly drain, a biopsy of the perforation edges and a collection of the digestive fluid within the pleural cavity. The thoracic part of the operation consisted of an



**Fig. 1. Sections of thoracoabdominal CT scan**



**Fig. 2. Intraoperative image of the intervention**

anterior thoracotomy through the 6th left intercostal space, which revealed the presence of digestive fluid within the pleural cavity, which was evacuated. Subsequently, an abundant saline lavage was performed with the placement of thoracic drains.

### 3. DISCUSSION

Esophageal perforation is an accident in which the esophagus tears or ruptures during instrumentation, vomiting, foreign body ingestion, surgical procedure or external trauma [2]. "It is usually iatrogenic, the result of endoscopic procedures such as esophageal dilatation for strictures and for achalasia in particular" [3]. "It can also result from surgery on tissue that is in close proximity to the esophagus. In about 15% of the cases, there is spontaneous rupture with no known pre-existing pathology of the esophagus. This is mostly related to intense vomiting or severe retching, which probably

causes an increase in intra-abdominal pressure" [4]. "This clinico-pathologic entity, first described by Hermann Boerhaave in 1724, was originally called Boerhaave syndrome" [5].

Boerhaave's syndrome is a spontaneous rupture of the esophagus, which is aptly included in the theme of paroxysmal deep mediastinal pain. Its relative rarity and the frequently overlooked early signs mean that the diagnosis is often made late, which makes the prognosis of this condition more difficult [6].

This pathology appears most frequently in men over 40 years of age. However, no age group is spared and we can cite cases found in newborns which are characterized by the right seat of the leakage [7].

Some authors consider that the term "spontaneous" rupture is inappropriate, because the lesion is caused by a sudden increase in

intra-esophageal pressure above the critical rupture level. It is violent vomiting that most often generates this laceration. The absence of serosa does not protect the organ from rupture. During vomiting, the lower esophagus can dilate up to 5 times its normal diameter under the effect of pressure. This phenomenon explains not only why rupture can occur, but also why it most often occurs in the lower third of the esophagus, and why the gastric contents (often filled with abundant food, but also septic) are injected under pressure into the posterior mediastinum. The contiguous pleura is regularly ruptured and the effusion then proceeds to the pleural cavity. The distal esophagus is closer to the left pleura (the middle esophagus closer to the right pleura); this explains why the pleural is more frequent on the left. If left untreated, the result will be mediastinitis and its septic morbidity which will progress to death [6].

“The classic clinical presentation as usually described in the literature is of overindulgence in food or drink with vomiting followed by severe chest pain, dyspnoea, mediastinal or subcutaneous emphysema and cardiovascular collapse; however, some reviews suggest that the presence of the entire complex of symptoms is rare, and therefore reliance on a 'classic' presentation may be misleading” [8].

Pain is the earliest and most consistent symptom [2]. “It is poorly relieved by narcotics. Usually it is a pleuritic left-sided chest pain which may radiate to the substernal area, epigastrium or back. Swallowing exaggerates the pain and it may cause coughing if there is a pleural tear. Sometimes the patient may collapse and dyspnea usually develops after the onset of pain” [8]. Fever appears quickly after the pain but is present in only 66% of cases [9]. Subcutaneous emphysema is a highly suggestive sign of the esophageal perforation and appears between 4 and 12 hours. Respiratory signs are characterized by dyspnea, cyanosis, and sometimes acute respiratory distress. The presence of pneumomediastinum is sometimes identified by the mediastinal crunch sound of Hamman [2].

Complementary examinations are aimed at confirming the existence of esophageal perforation, its location and its local and general repercussions. Indirect signs of perforation can be seen on standard radiology films, but they are less efficient than CT scans [10]. The cervicothoracic-abdominal CT scan can detect

the level of the leak, contamination of surrounding tissues, and the existence of collections. The CT scan is more accurate in detecting small amounts of air or fluid in the mediastinum, pleura and/or abdomen [1].

“Despite numerous reports documenting a wide range of experience in the treatment of esophageal perforation, recommendations regarding treatment remain controversial. Several factors are critical in determining the appropriate operative treatment such as the size and location of perforation, the presence of underlying esophageal disease and the interval between perforation and diagnosis” [8]. “Hence the management must be individualized. The different options for operative management are: primary closure, reinforced primary closure, resection of the esophagus, drainage alone, T-tube drainage, exclusion and diversion, and intra-luminal stent. Whichever mode of treatment is selected, the primary aim of the treatment must be to prevent further soilage from the perforation, to eliminate the infection produced by soilage, to restore the integrity and continuity of the gastrointestinal tract, and to restore and maintain adequate nutrition” [8,11,12].

The time to treatment determines the prognosis. For properly diagnosed and treated ruptures, mortality can be reduced (0%), but it can exceed 75% if the delay in treatment exceeds 48 hours [6].

#### 4. SUMMARY

Boerhaave syndrome or spontaneous oesophageal perforation is a lifethreatening condition which demands early diagnosis and urgent management. Yet despite the pressing necessity for diagnosis, it may go unrecognised, mainly because the presenting picture mimics other common conditions and as a result, the initial crucial intervention is delayed. We report a case of an esophageal perforation due to a Boerhaave syndrome and review the principal features of this pathology.

#### 5. CONCLUSION

Boerhaave syndrome is one of the most serious emergencies. The prognosis depends greatly on early diagnosis and proper treatment. Urgent and appropriate surgery remains the gold standard of treatment.

## CONSENT

As per international standard or university standard, patient(s) written consent has been collected and preserved by the author(s).

## ETHICAL APPROVAL

As per international standard or university standard written ethical approval has been collected and preserved by the author(s).

## COMPETING INTERESTS

Authors have declared that no competing interests exist.

## REFERENCES

1. Moor VD, Lemaire J, Rosière A, Michel L. Traitement des perforations œsophagiennes. 2019;15.
2. Rosière A, Michel L, Scavée V, Mulier S, Khoury A. Traitement des Perforations Œsophagiennes. 14.
3. Sánchez-Pernaute A, Aguirre EP, Talavera P, Valladares LD, de la Serna JP, Mantilla CS, et al. Laparoscopic approach to esophageal perforation secondary to pneumatic dilation for achalasia. Surg Endosc. Mai 2009;23(5):1106-9.
4. Søreide J, Viste A. Esophageal perforation: diagnostic work-up and clinical decision-making in the first 24 hours. Scand J Trauma Resusc Emerg Med. 2011;19(1):66.
5. Wolfson D, Barkin JS. Treatment of Boerhaave's syndrome. Curr Treat Options Gastro. févr 2007;10(1):71-7.
6. Honoré P, Roover AD, Detry O, Detroz B, Meurisse M. Le Syndrome de Boerhaave. 2.
7. Malledant Y, Tanguy M, Artus M, Cardin JL, Launois B, Saint-Marc C. La rupture spontanée de l'oesophage. :6.
8. Janjua KJ. Eponyms in Medicine Revisited.: 6.
9. Jougon J, Delcambre F, MacBride T, Minniti A, Velly JF. La mortalité des perforations instrumentales de l'œsophage est élevée: expérience de 54 cas traités. In: Annales de chirurgie. Elsevier. 2002;26-31.
10. Kowalczyk L, Forsmark CE, Ben-David K, Wagh MS, Chauhan S, Collins D, et al. Algorithm for the management of endoscopic perforations: a quality improvement project. American Journal of Gastroenterology. 2011;106(6): 1022-7.
11. Blichert-Toft M. Spontaneous Oesophageal Rupture: An Evaluation of the Results of Treatment 1944-1969. Scandinavian Journal of Thoracic and Cardiovascular Surgery. 1971;5(2):111-5.
12. Brewer III LA, Carter R, Mulder GA, Stiles QR. Options in the management of perforations of the esophagus. The American Journal of Surgery. 1986; 152(1):62-9.

© 2023 Bakouri et al.; This is an Open Access article distributed under the terms of the Creative Commons Attribution License (<http://creativecommons.org/licenses/by/4.0>), which permits unrestricted use, distribution, and reproduction in any medium, provided the original work is properly cited.

Peer-review history:

The peer review history for this paper can be accessed here:  
<https://www.sdiarticle5.com/review-history/98311>