



A Giant Fecolith in Pelvic Acute Appendicitis: A Case Report

**Mohamed M Elgeldawy^{a*}, Fahad Taraheeb Alajmi^a
and Hamad Alasnea^a**

^a *Department of Surgery, Al Adan Hospital, Ministry of Health, Kuwait.*

Authors' contributions

This work was carried out in collaboration among all authors. All authors read and approved the final manuscript.

Article Information

Open Peer Review History:

This journal follows the Advanced Open Peer Review policy. Identity of the Reviewers, Editor(s) and additional Reviewers, peer review comments, different versions of the manuscript, comments of the editors, etc are available here: <https://www.sdiarticle5.com/review-history/126071>

Case Report

Received: 27/08/2024

Accepted: 02/11/2024

Published: 06/11/2024

ABSTRACT

Calcified deposits in the lumen of the appendix are called appendicolith. The diameter of these appendicoliths is usually smaller than 1 cm. A giant Appendicolith is a rare faecolith larger than 2 cm. Usually, these giant appendicoliths are diagnosed by radiological investigations (such as computed tomography or X-rays of the abdomen) as the patients with giant appendicoliths have no complaints. Obstruction of the appendicular lumen by appendicolith not only increases the risk of acute appendicitis but also increases the risk of complications such as abscess formation and perforation. Our case report is for a 23-year-old gentleman who presented to the casualty with a history of right iliac fossa pain, nausea, vomiting, loose motion and loss of appetite for 2 days. A radio-opaque shadow in the pelvis was seen in an X-ray of the abdomen. An intravenous (IV) contrast-based abdominal computed tomography (CT) revealed acute appendicitis with a calcified 2.5 cm giant appendicolith. laparoscopic appendicectomy was performed. The patient was doing well postoperatively with no postoperative complications, and the patient was discharged home after one day. Two weeks later, the patient was reviewed in the surgical outpatient clinic (SOPD) with no complaints.

*Corresponding author: E-mail: thesurgeon76@yahoo.com, thesurgeon1976@gmail.com;

Cite as: Elgeldawy, Mohamed M, Fahad Taraheeb Alajmi, and Hamad Alasnea. 2024. "A Giant Fecolith in Pelvic Acute Appendicitis: A Case Report". *Asian Journal of Case Reports in Surgery* 7 (2):500-505. <https://journalajcrs.com/index.php/AJCRS/article/view/574>.

Keywords: Appendicitis; laparoscopic appendectomy; giant appendicolith; general surgery.

1. INTRODUCTION

Acute appendicitis is one of the most common causes of emergent surgeries [1]. Appendicolith and gastrointestinal infections cause acute inflammation of the appendix [2]. Obstruction OF the appendicular lumen either by appendicoliths, lymphoid hyperplasia, tumours, or foreign bodies explains the pathophysiology of acute appendicitis in most cases. The appendicular lumen obstruction leads to intraluminal pressure rise, the collapse of lymphatic vessels, collapsed veins, and decreased arterial flow, consequently leading to necrosis and perforation [3,4]. Complications of acute appendicitis such as perforation or abscess formation are more common with appendicolith. In literature, the incidence of a giant appendicolith is rare, with the largest measuring 3.5 cm in diameter [5]. However, most cases of appendicoliths are asymptomatic, it may cause intermittent chronic abdominal pain and is associated with an increased risk of acute appendicitis, perforation and abscess formation [6,7,8]. Appendicolith may also present as a colicky pain, in which stones in the urinary system must be considered [9]. Gallstone ileus, renal or extruded vesical calculi, phlebolith, calcified uterine fibroid tumor, lithopedion, genitourinary tract calcifications, ovarian tumours, rejected renal allograft, calcified lymphatic ganglia, foreign bodies, or radiologic artefact are the differential diagnoses of calcifications in the right iliac fossa [10,11].

2. CASE REPORT

A previously healthy 23-year-old gentleman presented to the casualty complaining of abdominal pain for 2 days. Initially, The pain started around the umbilicus and then migrated to the Right Iliac Fossa. The pain was acute in onset and continuous in nature associated with two times of nausea and vomiting. There was no change in bowel and bladder habits. On physical examination, the vital signs of the patient were within normal range. The abdomen was soft and lax, with mild tenderness at the lower right abdomen. Other signs of cute appendicitis such as Psoas test, Obturator test, and Rovsing sign were negative. His complete blood count on admission showed that the WBC was 14.7 (Neutrophils =10.6), and haemoglobin and platelets were within normal limits. A radio-opaque shadow in the pelvis was seen in an X-

ray of the abdomen. An intravenous (IV) contrast-based abdominal computed tomography (CT) revealed acute appendicitis with a calcified 2.5 cm giant appendicolith with surrounding fat stranding and minimal free fluid in the pelvis. The patient was admitted to the ward, and he was kept NPO, and IV fluids were started with Normal Saline. IV antibiotics (Ceftriaxone and Metronidazole) were initiated. The patient was shifted to the ward to be prepared for laparoscopic appendectomy. Skeletonization of the appendix was done by diathermy till the proper appendicula base, which was ligated using the regular end loop (the proper base was not so wide as seen in the operative image). The appendix was extracted by endobag. No drains were used. The postoperative day was smooth, and on the post-operative second day, he was discharged home from the hospital. At the follow-up after 2 weeks, the patient was well, and surgical stitches were removed.

3. DISCUSSION

Appendicoliths are solid deposits within the lumen of the appendix that are composed of faecal matter and mineral deposits [12]. The size of these appendicoliths is usually less than 1 cm. If their size is larger than 2 cm, then they are called giant appendicoliths [12]. In literature, the largest giant appendicolith was 3.5 cm in diameter in a patient with Crohn's disease and stump appendicitis (Our case had 2.5cm faecolith). In many studies, appendicoliths have been reported as the cause of 20%–40% of acute appendicitis. The risk factor of acute appendicitis because of appendicolith is male patients under 35 years of age (our case is 23 years old) and the position of the appendix is retrocecal [13]. The proximal appendiceal lumen obstruction results in closed-loop obstruction, which leads to an increase in luminal pressure. This intraluminal pressure increase can lead to a series of events, from congestion and ischemia of the appendiceal wall to gangrene and perforation if unresolved [1]. The perforation and abscess formation incidence in appendicitis associated with appendicoliths is 39.4%–50% [1]. In various studies, appendicoliths were suggested to have 100% specificity for the diagnosis of acute appendicitis [14,15]. On the other hand, some researchers have demonstrated the possibility of an appendicolith without acute appendicitis [16-18]. There is a big controversy between surgical versus

conservative management with antibiotics for the treatment of appendicitis. However, various studies showed that conservative management for acute appendicitis because of an

appendicolith has a higher rate of complications [1]. We managed our patient laparoscopically, and no complications either intraoperative or post-operative were found.

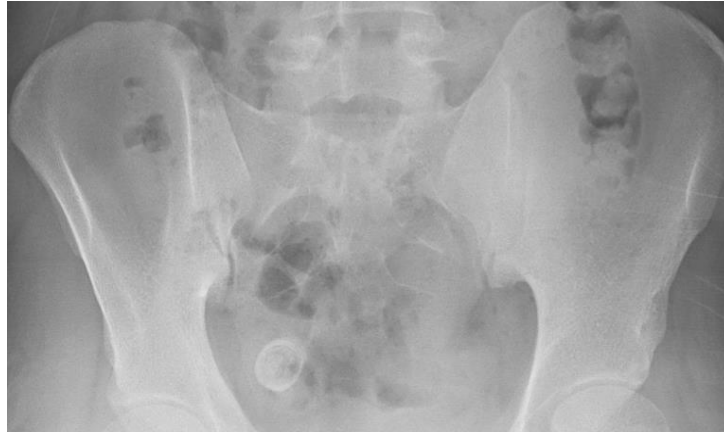

Fig. 1. Pelvic X-ray shows a radio-opaque shadow at the pelvis

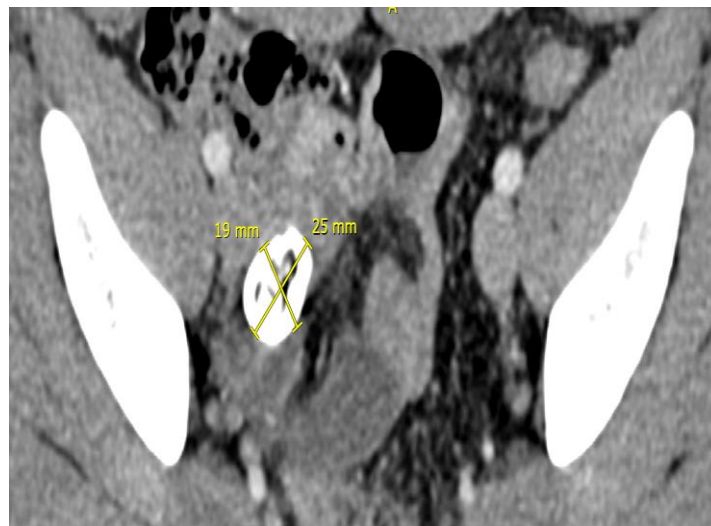
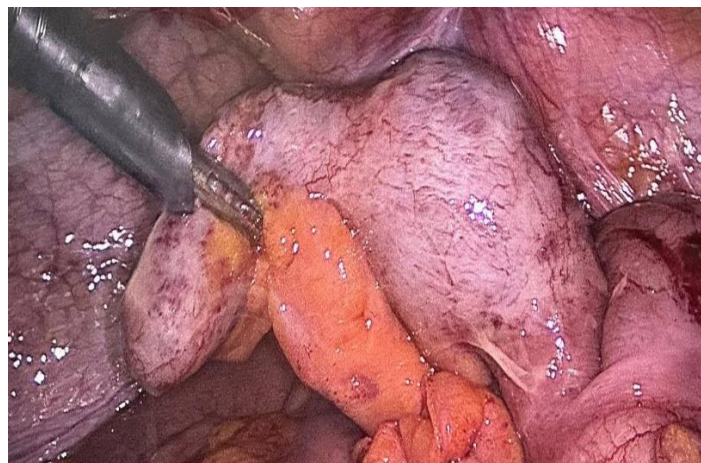


Fig. 2. Axial CT of the abdomen image shows hyperdense calcification in the pelvis



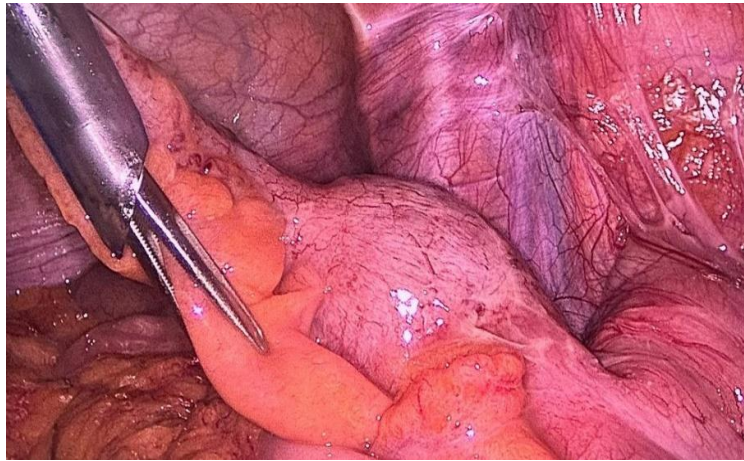


Fig. 3. Intraoperative images show an inflamed dilated appendix

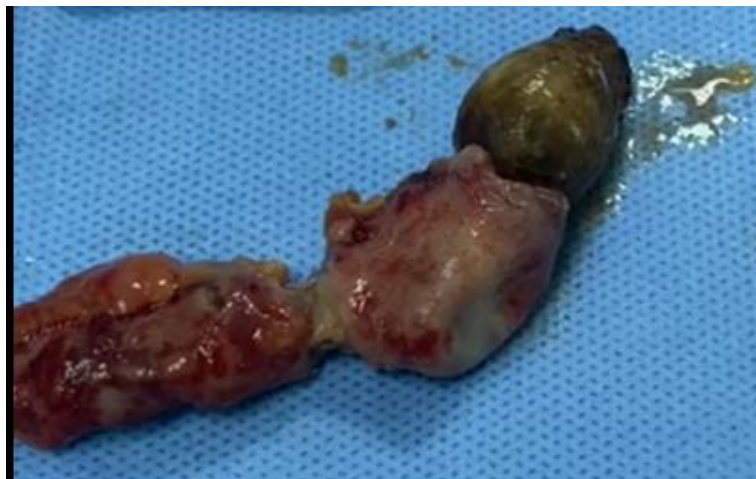
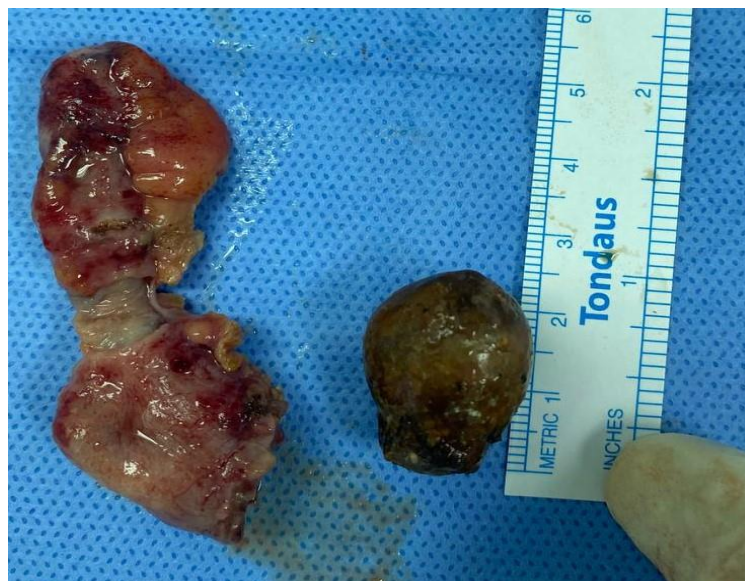
Fig. 4. Postoperative images show extracted appendicolith of about 2.5 cm

4. CONCLUSION

Giant appendicoliths are rare and their clinical presentation can sometimes be deceptive. However, when complicated, they can associate acute appendicitis with the risk of perforation, abscess formation, and peritonitis for which an emergency appendectomy is mandatory.

DISCLAIMER (ARTIFICIAL INTELLIGENCE)

Author(s) hereby declare that NO generative AI technologies such as Large Language Models (ChatGPT, COPILOT, etc) and text-to-image generators have been used during writing or editing of this manuscript.

CONSENT

Written informed consent was obtained from the patient for publication of this case report and accompanying images.

ETHICAL APPROVAL

As per international standards or university standards, written ethical approval has been collected and preserved by the author(s).

COMPETING INTERESTS

Authors have declared that no competing interests exist.

REFERENCES

1. Pahissa RA, Lin-Hurtubise KM. Giant appendicolith: a case report and review of the literature. *Mil Med.* 2020;185(9–10): E1851-E1853.
2. Kaya B, Eris C: Different clinical presentation of appendicolithiasis. The report of three cases and review of the literature. *Clin Med Insights Pathol.* 2011; 4:1-4. DOI:10.4137/CPath.S6757.
3. Flum DR. Acute Appendicitis — Appendectomy or the “Antibiotics First” Strategy. *N Eng J Med.* 2015;372(20): 1937-1943.
4. Petroianu A, Villar Barroso TV. Pathophysiology of Acute Appendicitis. *JSM Gastroenterology and Hepatology.* 2016;4(3):4-7.
5. Scroggie DL, Al-Whouhayb M: Asymptomatic giant appendicolith managed conservatively. *J Surg Case Rep.* 2015;rjv149. DOI:10.1093/jscr/rjv149.
6. Grimes C, Chin D, Bailey C, Gergely S, Harris A. Appendiceal faecoliths are associated with right iliac fossa pain. *Ann R Coll Surg Engl.* 2010;92(1):61-64.
7. Vyas RC, Sides C, Klein DJ, Reddy SY, Santos MC. The ectopic appendicolith from perforated appendicitis as a cause of tuba ovarian abscess. *Pediatr Radiol.* 2008;38(9):1006-1008.
8. Thapa N, Shrestha O, Basukala S, Shrestha K, Bhugai N, Joshi N, Gurung S. Case of giant appendicolith: A common ailment with a rare finding. *Clinical Case Reports.* 2023;11(6).
9. Teke Z, Kabay B, Erbiş H, Tuncay ÖL. Appendicolithiasis causing diagnostic dilemma: a rare cause of acute appendicitis (report of a case). *Ulus Travma Acil Cerrahi Derg.* 2008;14(4):323-325.
10. Salahi M, Patel H, Knuttinen MG. Calcified Pelvic Masses on Radiographs: A Case Report and Discussion. *Internal Medicine.* 2015;54:1451-1454.
11. Singh H, Neutze JA, Enterline JR. Abdominal Calcifications. In: Neutze JA, Enterline JR, Singh H. Eds., *Radiology Fundamentals: Introduction to Imaging & Technology*, Springer. 2015;157-162.
12. Rampersad CA, Rampersad FS, Ramraj PR, Seetahal VV. Case of a Giant Appendicolith. *Cureus.* 2022;14(2):e22034.
13. Hávez A, Blanco R, Chávez M, Pascual S, Hernández D, Valdés J. Giant Appendicolith in Acute Exacerbation of Chronic Appendicitis: Case Report and Literature Review. *Surgical Science.* 2017; 8:457-463.
14. Kim D, Butterworth SA, Goldman R. Chronic Appendicitis in Children. *Canadian Family Physician.* 2016;62:e304-e305.
15. Rao PM, Eittenberg J, McDowell RK, Rhea JT, et al. Helical Computed Tomographic Incidence and Characterization of Appendicoliths in 100 Patients with Appendicitis. *Emergency Radiology.* 1997; 4:55-61.
16. Lowe LH, Penney MW, Scheker LE, Perez R, et al. Appendicolith revealed on CT in Children with Suspected Appendicitis: How Specific Is It in the Diagnosis of

- Appendicitis? AJR American Journal of Roentgenology. 2000;175:981-984.
17. Huwart L, El Khoury M, Lesavre A, Phan C, et al. Le stercolithe est-il un signe fiable d'appendicite? [Is Appendicolith a Reliable Sign for Acute Appendicitis at MDCT?] Journal de radiologie. 2006;87:383-387.
18. Ramdass MJ, Sing QY, Milne D, Mooteeram J. et al. Association between the Appendix and the Fecalith in Adults. Canadian Journal of Surgery. 2015;58:10-14.
Available:<https://doi.org/10.1503/cjs.002014>.

Disclaimer/Publisher's Note: The statements, opinions and data contained in all publications are solely those of the individual author(s) and contributor(s) and not of the publisher and/or the editor(s). This publisher and/or the editor(s) disclaim responsibility for any injury to people or property resulting from any ideas, methods, instructions or products referred to in the content.

© Copyright (2024): Author(s). The licensee is the journal publisher. This is an Open Access article distributed under the terms of the Creative Commons Attribution License (<http://creativecommons.org/licenses/by/4.0>), which permits unrestricted use, distribution, and reproduction in any medium, provided the original work is properly cited.

Peer-review history:

The peer review history for this paper can be accessed here:

<https://www.sdiarticle5.com/review-history/126071>