

Evaluation of Functional and Radiological Outcome of Arthroscopic-Assisted Anatomical Coracoclavicular (CC) and Acromioclavicular (AC) Ligament Reconstruction in Chronic AC Joint Dislocation

Muhammad Hafiz Daud, Lim Wee Cheong, Ang Xi Yuan, Che Wan Mohd Shaiful Nizam, Siti Hawa Tahir

Arthroscopy Sports Injury Unit, Orthopedic Department, Hospital Kuala Lumpur, Kuala Lumpur, Malaysia
Email: muhdhafizmd@gmail.com

How to cite this paper: Daud, M.H., Cheong, L.W., Yuan, A.X., Nizam, C.W.M.S. and Tahir, S.H. (2024) Evaluation of Functional and Radiological Outcome of Arthroscopic-Assisted Anatomical Coracoclavicular (CC) and Acromioclavicular (AC) Ligament Reconstruction in Chronic AC Joint Dislocation. *Journal of Biosciences and Medicines*, 12, 223-237.

<https://doi.org/10.4236/jbm.2024.123019>

Received: January 19, 2024

Accepted: March 17, 2024

Published: March 20, 2024

Copyright © 2024 by author(s) and Scientific Research Publishing Inc.
This work is licensed under the Creative Commons Attribution International License (CC BY 4.0).

<http://creativecommons.org/licenses/by/4.0/>



Open Access

Abstract

Introduction: Acromioclavicular (AC) joint dislocation is a common shoulder injury, comprising 9% - 12% of shoulder girdle injuries. Optimal management remains challenging, with treatment decisions guided by the Rockwood classification system. Controversies surround grade III injuries, necessitating further classification. Non-operative treatment has shown favorable outcomes, while surgical interventions vary. Anatomical coracoclavicular reconstruction (ACCR) has demonstrated biomechanical advantages over traditional methods. Arthroscopic techniques offer advantages, minimizing deltoid detachment and allowing concurrent pathology identification. This study evaluates the outcomes of arthroscopic-assisted ACCR in chronic AC joint dislocation. **Surgical Technique:** Arthroscopic-assisted ACCR involves meticulous portal placement, tendon graft harvesting, diagnostic arthroscopy, and coracoid exposure. The clavicle tunnels were made to mimic the conoid and trapezoid ligament positions, using FibreTape#2 loop and Dog Bone Button for correct placement against the coracoid base, and passing the semitenosus graft through to reconstruct the conoid ligament, reduction done and graft follow through for anatomical reconstruction. **Methods:** A retrospective cohort study at Hospital Kuala Lumpur analyzed 35 patients undergoing arthroscopic-assisted ACCR for Rockwood grade III - V AC joint dislocations. Inclusion criteria encompassed trauma ≥ 3 weeks prior, no prior shoulder injuries, and ≥ 12 -month follow-up. Functional and radiological assessments utilized ASES scores and coracoclavicular distances, respectively. Statistical anal-

ysis employed descriptive statistics and logistic regression. **Results:** The mean age was 38.9 years (SD 11.26), and 34 of 35 patients were male. Grade IV injuries were predominant (37.1%). Waiting time for surgery averaged 234.9 days. Functional improvement was substantial postoperatively (ASES: 55.5 to 88.9). Radiological outcomes demonstrated reduced coracoclavicular distances and maintained reduction. No significant correlation was observed between injury grade and outcomes. **Conclusion:** Arthroscopic-assisted ACCR for chronic AC joint dislocation yields significant functional and radiological improvement, irrespective of injury grade. Waiting time for surgery exhibits minor impact on outcomes, emphasizing the procedure's efficacy. Concomitant injuries do not impede success, highlighting the versatility of this approach in managing shoulder instability. The study contributes valuable insights into the nuanced management of chronic AC joint dislocations and supports the adoption of arthroscopic-assisted ACCR as a viable treatment option.

Keywords

Arthroscopic-Assisted Anatomical Coracoclavicular and Acromioclavicular Ligament Reconstruction (AACR), Chronic Acromioclavicular Dislocation, ASES Score, Rockwood Classification

1. Introduction

The incidence of acromioclavicular (AC) joint dislocation accounts for 9% to 12% of shoulder girdle injuries [1], with an overall occurrence of 1.8 - 2.0 per 10,000 individuals annually in the general population [2] [3]. Risk factors include male gender and younger age. In the athletic population, the prevalence rises to 9.2 per 1000 person-years, predominantly comprising low-grade sprains [4]. Despite its frequency, optimal management remains challenging. Treatment decisions, traditionally guided by the Rockwood classification system, differentiate nonoperative measures for minor displacements (grades I and II) and operative interventions for severe displacements (grades IV - VI). Controversy surrounds grade III injuries, with debates over early surgery versus conservative approaches [5] [6] [7] [8] [9]. A recent proposal by the ISAKOS committee suggests extending grade 3 into 3A (stable) and 3B (unstable) types. They argue that grade 3B injuries are often unsuccessful with conservative treatment, adding nuance to the management dilemma in AC joint dislocations [10].

Non-operative treatment has demonstrated favorable outcomes in various studies addressing AC joint dislocation (grades I - III) [11] [12]. For type III AC joint dislocations, surgical intervention is proposed based on patient-specific factors such as age, activity level, arm dominance, and surgical risk [13] [14]. The literature offers a plethora of surgical techniques for addressing this injury, including primary repair of coracoclavicular ligaments, augmentation with autogenous tissue (coracoacromial ligament) [15], use of absorbable/nonabsorbable sutures, prosthetic material augmentation, and coracoclavicular stabilization em-

ploying metallic screws [16].

Traditionally, the Weaver-Dunn procedure, involving coracoacromial ligament transfer, has been a popular choice for surgically treating chronic AC joint dislocation [15]. However, a biomechanical study by Mazocca *et al.* revealed that the modified Weaver-Dunn method exhibited more laxity than anatomical coracoclavicular reconstruction (ACCR), emphasizing that ACCR better approximates the intact state, reducing anterior and posterior translation and restoring the function of acromioclavicular and coracoclavicular ligaments [17].

Alternative method of arthroscopic reconstruction, pioneered by Wolf and Pennington, minimizes risk of deltoid detachment and extensive incision while enabling simultaneous identification of concomitant glenohumeral pathology [18]. Intra-articular pathology incidence is reported between 15% - 18%, with high-grade AC joint dislocations reaching up to 42%, necessitating additional treatments in 29% [19]. Our observational study aligns with this, revealing 65.9% of patients with associated intraarticular injuries, of which 74% required supplementary debridement or reconstructive surgery [20]. Relying solely on biological grafts without stable fixation may increase failure risk. Reports suggest varied fixation methods to protect tendon grafts during healing. The suspensory stabilization technique, using button fixation, strengthens and safeguards anatomical reconstruction during the healing process [9] [21].

This study aimed to assess the functional and radiological outcomes of arthroscopic-assisted Anatomical Coracoclavicular (CC) and Acromioclavicular (AC) ligament reconstruction in high-grade chronic AC joint dislocation at Hospital Kuala Lumpur. Objectives included evaluating the correlation between injury grade and functional/radiological outcomes, examining the impact of the duration from injury to surgery on outcomes, and exploring the relationship between concomitant intraarticular arthroscopic findings and the functional/radiological outcomes of the reconstruction procedure for chronic AC joint dislocation.

2. Surgical Technique

In the surgical procedure, the patient was positioned in the beach chair, and meticulous preparation involved indexing the shoulder and knee before draping. The semitendinosus tendon was harvested, its ends whipstitched with No. 2 Ethibon suture, forming torpedo-shaped ends. A standard posterior portal allowed diagnostic arthroscopy, addressing intraarticular pathologies. An antero-inferior portal was carefully established lateral to the coracoid within the rotator interval, preserving the superior and middle glenohumeral ligaments. An antero-superior portal facilitated visualizing the coracoid base, with precautions taken to avoid supraspinatus tendon injury. The coracoid base was exposed, and a 2- to 3-cm incision near the lateral clavicle allowed access for subsequent steps. Hohmann retractors exposed the distal clavicle for the AC joint procedure. The AC drill guide facilitated drilling a trans clavicular-coracoid tunnel, with fluo-

roscopic confirmation. The coracoid was then prepared for graft placement.

Sequentially, tunnels were created in the clavicle to mimic conoid and trapezoid ligament locations. FibreTape#2 loop and Dog Bone Button were used, ensuring proper positioning against the coracoid base. The semitendinosus graft was passed through tunnels, recreating the conoid ligament. Careful tissue removal from the lateral coracoid surface allowed graft healing. Vertical tunnels were created for graft passage around the coracoid base, securing the graft with meticulous techniques. The AC joint was reduced, applying controlled force, and the FibreTape was tightened, with slight over-reduction for anticipated loss. The acromion tunnel was created under fluoroscopic guidance, with precise positioning and tunnel creation. Nitinol wire served as a relay suture for graft passage through the lateral clavicle tunnel to the superior acromion surface. The graft was then flipped back through a pathway created atop the acromion cortex. Finally, the graft ends, including the medial tunnel limb and acromion limb, were sutured together using Ethibon 2# or fibre wire 2# (Figure 1, Figure 2). The wound was irrigated and closed conventionally.

This comprehensive reconstruction involved a step-by-step approach, combining arthroscopic and fluoroscopic techniques. Emphasis was placed on anatomical precision, including careful portal placement, tunnel creation, and graft passage to recreate the conoid and trapezoid ligaments. The meticulous process aimed at restoring stability to the AC joint, showcasing the integration of advanced arthroscopic and orthopedic principles for optimal patient outcomes.

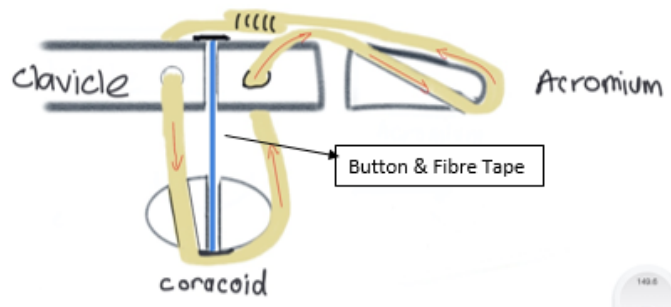


Figure 1. Front view of the reconstruction.

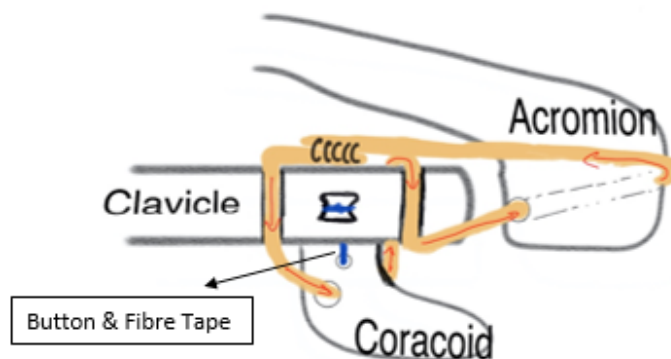


Figure 2. Superior view of the reconstruction.

3. Method

This retrospective cohort study conducted at Hospital Kuala Lumpur evaluated patients who underwent arthroscopic-assisted anatomical acromioclavicular (AC) and coracoclavicular (CC) ligament reconstruction between January 1, 2015, and June 30, 2021. A total of 36 procedures were performed for Rockwood grade III to V AC joint disruptions using free tendon autograph and high-strength suture augmentation with button and fiber tape. One patient defaulted follow-up, leaving 35 patients for analysis. Among the 35 patients, diverse occupational backgrounds were represented, including security guards, gardeners, drivers, office workers, IT engineers, and clerks. Some participants were actively involved in sports, while others were not.

Inclusion criteria comprised young and middle-age adult patients diagnosed with AC joint dislocation or instability who underwent surgery at least 3 weeks after trauma, excluding hamstring autograft reconstruction within this time-frame. Participants needed a minimum 12-month follow-up and no prior shoulder injuries. Exclusion criteria included concomitant clavicle or coracoid fractures, previous shoulder pain or surgery, different AC joint stabilization techniques, bilateral shoulder involvement, and incomplete data.

Patients included in the study underwent a comprehensive AC joint reconstruction procedure combining arthroscopic and fluoroscopic techniques, performed with the patient in the beach chair position. The semitendinosus tendon was harvested and meticulously prepared for graft placement, aiming to recreate the conoid and trapezoid ligaments. Sequential tunnel creation and precise graft passage around the coracoid base were undertaken to restore AC joint stability, emphasizing anatomical precision and a step-by-step approach.

Data collected included demographics, injury details, duration from injury to surgery, arthroscopic findings, complications, and functional and radiographic assessments. Functional assessment used the American Shoulder and Elbow Surgeon Scoring System. Radiographic assessment measured the Coracoclavicular (CC) distance, comparing affected and contralateral shoulders. Two orthopedic doctors conducted the analysis, evaluating reduction status, ASES and Constant scores, and recording complications as major or minor.

Statistic Method

Descriptive statistics are presented as median (range from 25th - 75th percentiles) or frequency and percentage values as appropriate. Inferential statistic will be used *i.e.* a univariate and multivariate logistic regression will be performed to identify factors that affect clinical efficacy of treatment. All analyses will be carried out using SPSS statistical software (version 22, IBM, SPSS, Chicago, IL, USA). The threshold for statistical significance will be set at $p < 0.05$ (two-sided).

4. Results

Study was conducted on 35 patients (34 male) with high-grade AC injuries

(Rockwood grade III through V) who underwent AACCR. The average age at the time the procedure was performed was 40.4 years (range, 24 - 66 years) with mean age of 38.9 years old SD 11.26.

Demographic and surgical information and injury characteristics are summarized in **Table 1**.

This study was undertaken to assess the functional and radiological outcomes associated with arthroscopic-assisted anatomical reconstruction of the coracoclavicular (CC) and acromioclavicular (AC) ligaments in cases of high-grade chronic AC joint dislocation at Hospital Kuala Lumpur. The waiting time for the operation in this study had a mean duration of 234.9 days.

Patient's outcome is charted using ASES scoring which involves both subjective and objective assessments. The subjective part, a 100-point scale, gauges shoulder pain and daily living activities (ADL). Pain contributes 50 points, and the ADL component, comprising ten activities, and adds up to 50 points. Objectively, ASES evaluates tenderness, range of motion, and tests for various shoulder structures. The ASES score serves as a quantitative evaluation tool for assessing

Table 1. Demographic and Injury characteristics, Surgical Information.

Patient demographics	
No. shoulders	35
Men	34
Mean age, y (SD)	38.9 (11.26)
Injured shoulder	
Right	17
Left	18
Rockwood grade	
III	4
IV	13
V	18
Timing of surgery	
Greater than 90 d after injury	20
Less than 90 d after injury	15
Concomitant Injury	
None	15
Pasta lesion	4
SLAP 2 tear	5
SLAP 3 tear	3
SST tear	3
Subscapularis tear	1
Bicep tendinitis	2
ACJ OA	1
Distal end clavicle fracture	1

shoulder joint function and pain. It is not simply classified into binary categories of “good” or “bad”. Rather, the numerical result obtained offers insights into the overall shoulder performance and condition, with higher scores typically associated with improved function and reduced pain. Because current metrics are not available for patients with AC joint injuries, we utilized minimum changes from rotator cuff tears with final ASES score of 86.7 for the PASS.

As illustrated in **Figure 3**, in this study, the mean ASES score exhibited a preoperative value of 55.5, which significantly improved to 88.9 postoperatively. This indicates that patients experience increased satisfaction with postoperative treatment, transitioning from a fair level of satisfaction prior to the operation.

Radiological outcomes were assessed through two methods: coraco-clavicular distance and the status of acromioclavicular joint reduction during the final follow-up. A normal coracoclavicular distance falls within the range of 11 - 13 mm, with no more than a 5 mm difference between the left and right sides [22]. Acromioclavicular (AC) joint subluxation and dislocation indicate misalignment at the joint where the acromion and clavicle meet, with subluxation involving partial displacement and dislocation indicating complete separation [23].

Figure 4 delineates the progression of CC distance, revealing initial measurements of 18.3 preoperatively, a reduction to 6.5 postoperatively, and a stabilization at 8.7 during the final follow-up. Furthermore, **Figure 5** presents comprehensive study findings, indicating that at the ultimate follow-up, 2 cases persisted with dislocation, 18 cases maintained reduction, and 15 cases exhibited subluxation.

Regarding the correlation between the Grade of Injury and functional as well as radiological outcomes, it was observed that the mean functional score significantly improves postoperatively compared to the preoperative state as seen in **Table 2**. Notably, Grade 4 injuries exhibit the most substantial postoperative improvement in patient ASES score at 35.26%, surpassing Grade 3 (26.27%) and Grade 5 (34.16%).

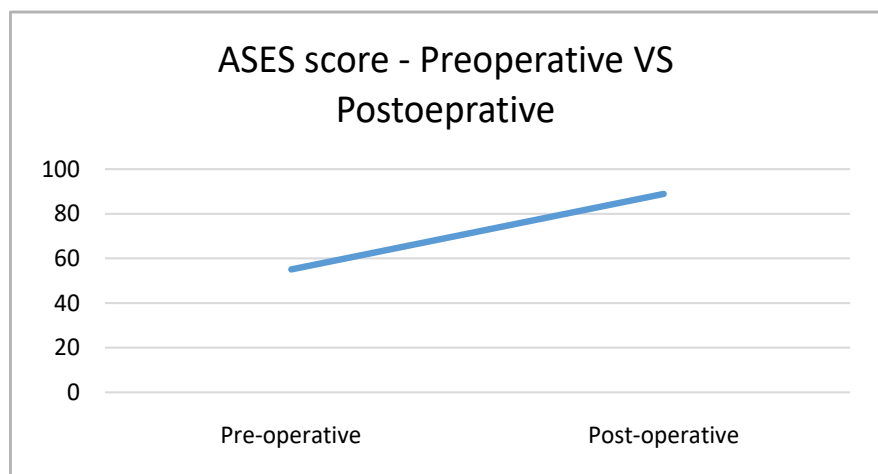


Figure 3. American shoulder and elbow surgeons (ASES) score pre-operative VS post operative.

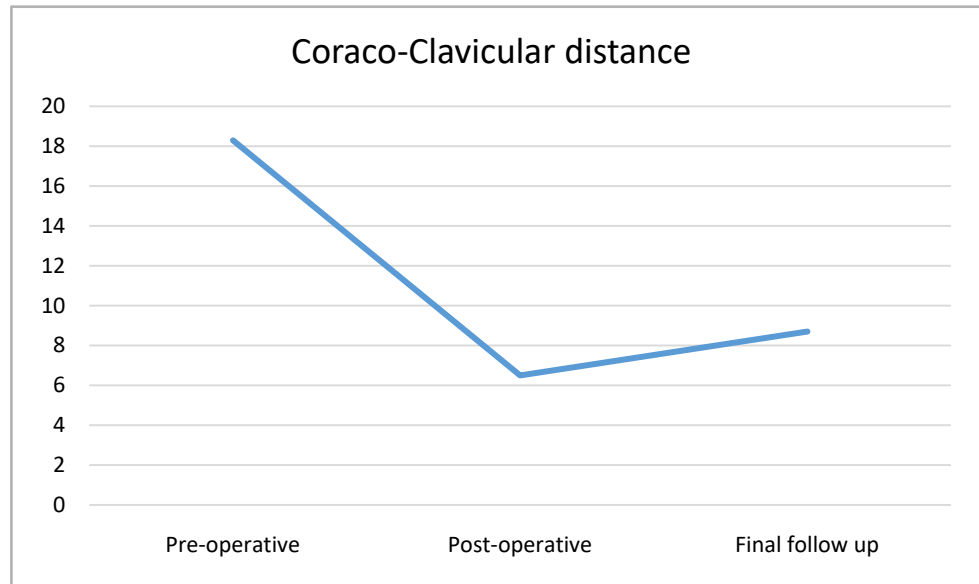


Figure 4. Coracoclavicular distance (in mm) pre-operative VS post operative.

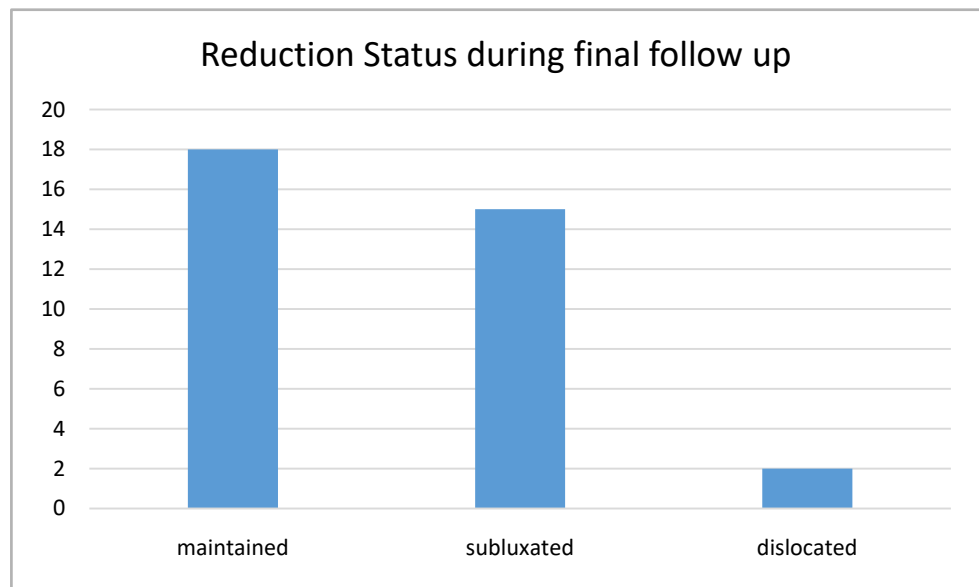


Figure 5. Status of acromioclavicular joint reduction pre-operative VS post operative.

Table 2. Grading of ACJ injury correlated with functional and radiological outcomes post AACR.

Grade of ACJ injury	Functional score (mean)		Radiological outcome—coracoclavicular distance in mm (mean)			Status of reduction (n)
	ASES pre Op	ASES post Op	Pre Op	Post Op	Final follow up	
3	50.73	77	20	7.4	8.06	M3, S2
4	57.59	92.85	18.08	6.08	8.61	M7, S5, D1
5	55.23	89.39	18	6.47	8.84	M8, S8, D1

M: Maintained, S: Subluxated, D: Dislocated.

Analyzing the mean CC distance difference before and after the operation, it is evident that all grades display consistently successful reduction, with no discernible superiority among them.

However, when considering the status of reduction, Grade 3 injuries demonstrate a higher percentage of maintained reduction (60%) compared to Grade 4 (53%) and Grade 5 (47%) injuries, respectively.

Meanwhile for waiting time to operation, instances where the operation was performed within 90 days of the trauma date exhibit a superior postoperative ASES score compared to operations conducted beyond the 90-day mark as demonstrated in **Table 3**.

The CC distance also demonstrates improvement postoperatively, with no significant variance based on the duration of waiting time to the operation.

However, when considering the correlation between the status of reduction and waiting time to operation, surgeries performed beyond 90 days showcase superior results in terms of maintained reduction (61.9%) compared to those conducted within 90 days of surgery (35%).

In this study, arthroscopic assessment identified concomitant injuries in 21 out of 35 cases. Among these, 7 cases exhibited rotator cuff pathology, 8 presented with labral pathology, 5 displayed bone joint and tendon pathology, and 1 showed a combination of pathologies.

In cases without concomitant pathology, the ASES score demonstrated significant improvement, increasing from 58.4 to 94.5. Conversely, combined pathology cases exhibited a remarkable ASES score improvement, rising from 41.67 to 90. Results for other concomitant injuries were consistently excellent postoperatively.

Radiological assessment, considering concomitant pathology, yields consistent results with a mean coracoclavicular distance ranging from 8 to 9.4 during the final follow-up. Intriguingly, there seems to be no clear association between concomitant injuries and shoulder instability, as evidenced by 5 cases of subluxation and 1 case of dislocation in those without concomitant injuries. Moreover, ACJ injuries with concomitant pathology also present sporadic occurrences of subluxation and dislocation as shown in **Table 4**.

5. Discussion

The acromioclavicular (AC) joint serves as a synovial joint that connects the acromion and the distal clavicle, while the medial aspect of the clavicle is linked to the sternum through the sternoclavicular joint. Stability of the distal clavicle is maintained by both the coracoclavicular (CC) ligament complex and the AC joint capsule [24]. Surgical reconstruction of the AC joint may be contemplated in the acute setting for separations classified as grades IV, V, and VI, as well as for grade III separations observed in individuals engaged in manual labor or competitive sports. Additionally, it may be considered for chronic grade III to VI separations when conservative treatments have proven ineffective [5] [6] [7].

Table 3. Grading of ACJ injury correlated with functional and radiological outcomes post AACR.

Duration to operation	Functional score (mean)		Radiological outcome—coracoclavicular distance in mm (mean)			Status of reduction (n)
	ASES pre Op	ASES post Op	Pre Op	Post Op	Final follow up	
<90 days	50.84	91.4	17	5.1428	8.0714	M 5, S 8, D 1
>90 days	51.5	87.65	19.9	7.33	9.238	M 13, S 7, D 1

M: Maintained, S: Subluxated, D: Dislocated.

Table 4. Concomitant injury diagnosed arthroscopically correlated with functional and radiological outcomes post AACR.

Concomitant injury	Functional score (mean)		Radiological outcome—coracoclavicular distance in mm (mean)			Status of reduction
	ASES pre Op	ASES post Op	Pre Op	Post Op	Final follow up	
None	56.35	87.83	18.43	6.78	9.14	M-8, S-5, D-1
Rotator cuff pathology	58.4	94.9	16.6	4.9	8	M-1, S-6
<i>PASTA Lesion</i>	<i>51</i>	<i>95.66</i>	<i>18.33</i>	<i>6</i>	<i>8.33</i>	<i>M-1, S-2</i>
<i>PASTA and SST tear</i>	<i>59.5</i>	<i>90</i>	<i>17</i>	<i>4.5</i>	<i>7.5</i>	<i>S-2</i>
<i>Partial SST Tear</i>	<i>50</i>	<i>100</i>	<i>13</i>	<i>3</i>	<i>8</i>	<i>S-1</i>
<i>Subscapularis and partial SST tear</i>	<i>86.7</i>	<i>97</i>	<i>14</i>	<i>4</i>	<i>8</i>	<i>S-1</i>
Labral pathology	53.3	89.2	20	6.4	8.3	M-4, S-3, D-1
<i>SLAP 2</i>	<i>56.86</i>	<i>93.6</i>	<i>19.4</i>	<i>6.2</i>	<i>7.6</i>	<i>M-2, S-3</i>
<i>SLAP 3</i>	<i>51.22</i>	<i>81.66</i>	<i>23.66</i>	<i>6.33</i>	<i>10</i>	<i>M-2, D-1</i>
Bone, Joint and biceps tendon pathology	52.8	83	17.4	7.8	9.4	M-4, S-1
<i>Bicep Tendinitis</i>	<i>48.5</i>	<i>77.5</i>	<i>17.5</i>	<i>9</i>	<i>9.5</i>	<i>M-2</i>
<i>ACJ OA</i>	<i>35</i>	<i>90</i>	<i>17</i>	<i>9</i>	<i>11</i>	<i>M-1</i>
<i>Chondral injury</i>	<i>64</i>	<i>70</i>	<i>15</i>	<i>5</i>	<i>10</i>	<i>S-1</i>
<i>Distal clavicle fracture</i>	<i>68</i>	<i>100</i>	<i>20</i>	<i>7</i>	<i>7</i>	<i>M-1</i>
Combined pathology						
<i>SLAP 2 and SST tear</i>	41.67	90	12	8	8	M-1

PASTA: partial articular supraspinatus tendon avulsion, SST: Supraspinatus, SLAP: Superior Labrum Anterior and Posterior, ACJ OA: Acromioclavicular joint osteoarthritis/M: Maintained, S: Subluxated, D: Dislocated.

Traditionally, the Weaver-Dunn procedure, involving coracoacromial (CA) ligament transfer, has been a widely employed surgical approach for chronic AC joint dislocation. However, a biomechanical study by Mazocca *et al.* revealed increased laxity in the modified Weaver-Dunn method compared to anatomical coracoclavicular (CC) reconstruction, especially in comparison to the intact state [25]. The study emphasized that anatomical CC reconstruction (ACCR) results in reduced anterior and posterior translation, closely approximating the intact state and effectively restoring the function of acromioclavicular and coracocla-

vicular ligaments.

Despite the efficacy of ACCR, the traditional open method for its implementation has seen a shift towards arthroscopy due to advancements in arthroscopic techniques, indicating a preference for arthroscopy over open methods in managing acromioclavicular joint disruption.

Multiple studies were done on clinical outcomes after open ACCR have been reported with generally good to excellent. Nicholas *et al.* [26], Tauber *et al.* [27], and Millett *et al.* [13] have independently reported mean ASES scores of 92 - 96 with 6 - 46 months follow-up after primary ACCR procedures. Our study is focused on investigating functional and radiographic outcomes post-arthroscopic anatomic coracoclavicular ligament reconstruction for Type III/V acromioclavicular joint injuries.

The primary outcome of our study indicates that patients undergoing arthroscopic-assisted anatomic coracoclavicular ligament reconstruction (AAACCR) for chronic type III, IV, and V Acromioclavicular joint injuries experience sustained and significant improvement in both clinical and radiographic outcomes, even when the surgery is performed beyond the 90-day mark. 75% of the patients reached a satisfactory threshold based on the ASES score (Figure 6), aligning with findings from a study conducted by Lukas Muench on open Anatomic Coracoclavicular Ligament Reconstruction for Type III/V Acromioclavicular Joint Injuries. Muench's study, involving 79 patients, demonstrated substantial and enduring enhancement in clinical and radiographic outcomes over a minimum 2-year follow-up, with 81% of patients achieving the substantial clinical benefit (SCB) after surgical reconstruction.

Additionally, our research reveals a limited or negligible correlation between the injury grade and functional as well as radiological outcomes. The key takeaway is that the mean postoperative ASES score consistently exceeds 86.7, regardless of the injury grade. Although the mean postoperative coracoclavicular distance falls within the normal range (8.06 to 8.84 mm), instances of subluxation or dislocation were observed during the final follow-up.

In our observation in this study, surgery performed within 90 days of the trauma date consistently demonstrate superior postoperative American Shoulder and Elbow Surgeons (ASES) scores compared to procedures conducted beyond the 90-day mark. The improvement in the coracoclavicular (CC) distance post-operatively remains consistent across both time frames, with no significant variance based on the duration of waiting time to the operation.

However, a crucial observation emerges when considering the correlation between the status of reduction and the waiting time to operation. Surgeries conducted beyond 90 days showcase slightly superior results in terms of maintained reduction (61.9%) compared to those performed within the initial 90 days of surgery (35%). This suggests that even in cases of chronic injury, favorable outcomes, particularly in terms of reduction maintenance, can still be achieved through AACCR surgery, emphasizing the importance of the optimal timing of the surgical intervention.

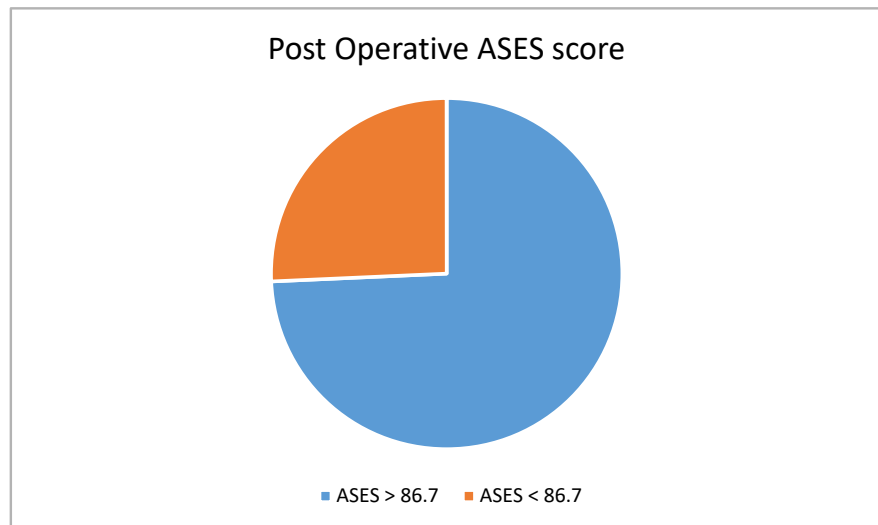


Figure 6. Overall post operative ASES score.

The incidence of intra-articular pathology has been reported to range from 15% to 18% [1]. A study by Arrigoni *et al.* in 2014 revealed that in cases of high-grade AC joint dislocation, the incidence of additional pathology could be as high as 42%, with 29% requiring further interventions [19]. Similarly, an observational study conducted at our center demonstrated that over half (65.9%) of our patients had associated intra-articular injuries, and among them, 74% necessitated additional debridement or reconstructive surgery [20].

In the course of this study, arthroscopic evaluation successfully detected associated injuries in 21 out of 35 cases. Among these, 7 cases manifested rotator cuff pathology, 8 demonstrated labral pathology, 5 revealed bone joint and tendon pathology, and 1 exhibited a combination of pathologies. This not only allows us to address acromioclavicular joint pathology but also provides an opportunity to manage other concurrent injuries. Additionally, it enables us to assess the correlation between concomitant injuries, the American Shoulder and Elbow Surgeons (ASES) score, and radiological outcomes.

Notably, cases without concomitant pathology saw a substantial increase from 58.4 to 94.5, while even cases with combined pathology exhibited remarkable improvement, rising from 41.67 to 90. Radiological assessments consistently showed a mean coraco-clavicular distance of 8 to 9.4 during the final follow-up, regardless of concomitant pathology.

Interestingly, there appears to be no clear association between concomitant injuries and shoulder instability, evident by subluxation and dislocation occurrences in both cases with and without additional injuries. Our findings highlight the efficacy of arthroscopic-assisted anatomic coraco-clavicular ligament reconstruction, emphasizing its positive impact on postoperative outcomes in acromioclavicular joint injuries. This study contributes valuable insights into the complex interplay between concomitant injuries and the success of surgical intervention in managing shoulder instability.

6. Conclusion

Patients undergoing AAACCR for chronic Type III-V AC joint injuries maintained significant improvement in clinical and radiographic outcomes. Duration to wait until operation does not show much significant difference in terms of ASES score as well as final status of reduction. Arthroscopic assisted reconstruction also helps to address other shoulder pathology, and also yes, ACJ injury alone with no concomitant injury shows better results in ASES score as compared to those with pathology. The study involved a small participant sample; future research could benefit from a larger cohort.

Ethics Approval

Informed consent was obtained from all participating patients in adherence to local protocols and guidelines. All procedures conducted in this study were aligned with ethical standards established by the institutional committee, and in accordance with the 1964 Helsinki Declaration and its subsequent amendments, or equivalent ethical standards.

The study, involving human material and data, strictly adhered to the principles outlined in the Declaration of Helsinki. Ethical approval for this research was granted by the Malaysia Medical Research & Ethics Committee, under the approval letter code NMRR ID-22-00628-1UD (IIR), received on March 6, 2023. This approval attests that the study maintained rigorous ethical standards, ensuring the protection of participants' rights, well-being, and confidentiality.

Conflicts of Interest

The author(s) declared no potential conflicts of interest with respect to the research, authorship, and publication of this article.

References

- [1] Pauly, S., Gerhardt, C., Haas, N.P. and Scheibel, M. (2009) Prevalence of Concomitant Intraarticular Lesions in Patients Treated Operatively for High-Grade Acromioclavicular Joint Separations. *Knee Surgery, Sports Traumatology, Arthroscopy*, **17**, 513-517. <https://doi.org/10.1007/s00167-008-0666-z>
- [2] Nordin, J.S., Olsson, O. and Lunsjö, K. (2020) Acromioclavicular Joint Dislocations: Incidence, Injury Profile, and Patient Characteristics from a Prospective Case Series. *JSES International*, **4**, 246-250. <https://doi.org/10.1016/j.jseint.2020.01.009>
- [3] Chillemi, C., Franceschini, V., Giudici, L.D., *et al.* (2013) Epidemiology of Isolated Acromioclavicular Joint Dislocation. *Emergency Medicine International*, **2013**, Article ID: 171609. <https://doi.org/10.1155/2013/171609>
- [4] Gowd, A.K., Liu, J.N., Cabarcas, B.C., *et al.* (2019) Current Concepts in the Operative Management of Acromioclavicular Dislocations: A Systematic Review and Meta-Analysis of Operative Techniques. *The American Journal of Sports Medicine*, **47**, 2745-2758. <https://doi.org/10.1177/0363546518795147>
- [5] Dias, J.J., Steingold, R.F., Richardson, R.A., *et al.* (1987) The Conservative Treatment of Acromioclavicular Dislocation. Review after Five Years. *The Journal of Bone and Joint Surgery British Volume*, **69**, 719-722.

- <https://doi.org/10.1302/0301-620X.69B5.3680330>
- [6] Ceccarelli, E., Bondi, R., Alviti, F., *et al.* (2008) Treatment of Acute Grade III Acromioclavicular Dislocation: A Lack of Evidence. *Journal of Orthopaedics and Traumatology*, **9**, 105-108. <https://doi.org/10.1007/s10195-008-0013-7>
- [7] Rolf, O., Hann von Weyhern, A., Ewers, A., *et al.* (2008) Acromioclavicular Dislocation Rockwood III-V: Results of Early versus Delayed Surgical Treatment. *Archives of Orthopaedic and Trauma Surgery*, **128**, 1153-1157. <https://doi.org/10.1007/s00402-007-0524-3>
- [8] Millett, P.J., Braun, S., Gobezie, R., *et al.* (2009) Acromioclavicular Joint Reconstruction with Coracoacromial Ligament Transfer Using the Docking Technique. *BMC Musculoskeletal Disorders*, **10**, Article No. 6. <https://doi.org/10.1186/1471-2474-10-6>
- [9] Scheibel, M., Dröschel, S., Gerhardt, C. and Kraus, N. (2011) Arthroscopically Assisted Stabilization of Acute High-Grade Acromioclavicular Joint Separations. *The American Journal of Sports Medicine*, **39**, 1507-1516. <https://doi.org/10.1177/0363546511399379>
- [10] Beitzel, K., *et al.* (2014) ISAKOS Upper Extremity Committee Consensus Statement on the Need for Diversification of the Rockwood Classification for Acromioclavicular Joint Injuries. *Arthroscopy-The Journal of Arthroscopic and Related Surgery*, **30**, 271-278. <https://doi.org/10.1016/j.arthro.2013.11.005>
- [11] Virk, M.S., Mazzocca, A.D., Bak, K., *et al.* (2015) Operative and Nonoperative Treatment of Acromioclavicular Dislocation: A Critical Analysis Review. *JBJS Reviews*, **3**, e5. <https://doi.org/10.2106/JBJS.RVW.N.00092>
- [12] Dunphy, T.R., Damodar, D., Heckmann, N.D., *et al.* (2016) Functional Outcomes of Type V Acromioclavicular Injuries with Nonsurgical Treatment. *Journal of the American Academy of Orthopaedic Surgeons*, **24**, 728-734. <https://doi.org/10.5435/JAAOS-D-16-00176>
- [13] Millett, P.J., Horan, M.P. and Warth, R.J. (2015) Two-Year Outcomes after Primary Anatomic Coracoclavicular Ligament Reconstruction. *Arthroscopy-The Journal of Arthroscopic and Related Surgery*, **31**, 1962-1973. <https://doi.org/10.1016/j.arthro.2015.03.034>
- [14] Allemann, F., Halvachizadeh, S., Waldburger, M., *et al.* (2019) Different Treatment Strategies for Acromioclavicular Dislocation Injuries: A Nationwide Survey on Open/Minimally Invasive and Arthroscopic Concepts. *European Journal of Medical Research*, **24**, Article No. 18. <https://doi.org/10.1186/s40001-019-0376-7>
- [15] Weaver, J.K. and Dunn, H.K. (1972) Treatment of Acromioclavicular Injuries, Especially Complete Acromioclavicular Separation. *The Journal of Bone and Joint Surgery*, **54**, 1187-1194. <https://doi.org/10.2106/00004623-197254060-00005>
- [16] Phadke, A., Bakti, N., Bawale, R. and Singh, B. (2019) Current Concepts in Management of ACJ Injuries. *Journal of Clinical Orthopaedics and Trauma*, **10**, 480-485. <https://doi.org/10.1016/j.jcot.2019.03.020>
- [17] Mazzocca, A.D., Santangelo, S.A., Johnson, S.T., Rios, C.G., Dumonski, M.L. and Arciero, R.A. (2006) A Biomechanical Evaluation of an Anatomical Coracoclavicular Ligament Reconstruction. *The American Journal of Sports Medicine*, **34**, 236-246. <https://doi.org/10.1177/0363546505281795>
- [18] Wolf, E.M. and Pennington, W.T. (2001) Arthroscopic Reconstruction for Acromioclavicular Joint Dislocation. *Arthroscopy-The Journal of Arthroscopic and Related Surgery*, **17**, 558-563. <https://doi.org/10.1053/jars.2001.23578>
- [19] Arrigoni, P., Brady, P.C., Zottarelli, L., *et al.* (2014) Associated Lesions Requiring

- Additional Surgical Treatment in Grade 3 Acromioclavicular Joint Dislocations. *Arthroscopy- The Journal of Arthroscopic and Related Surgery*, **30**, 6-10. <https://doi.org/10.1016/j.arthro.2013.10.006>
- [20] Nizam, C.W., Thangaraju, S., Muniandy, M. and Tahir, S.H. (2019) Associated Intraarticular Lesions Encountered during Arthroscopic Assisted Stabilization of Rockwood Type IV and V Acromioclavicular Joint Injuries. *International Journal of Science and Research*, **8**, 994-998.
- [21] Scheibel, M., Ifesanya, A., Pauly, S. and Haas, N.P. (2008) Arthroscopically Assisted Coracoclavicular Ligament Reconstruction for Chronic Acromioclavicular Joint Instability. *Arthroscopy and Sports Medicine*, **128**, 1327-1333. <https://doi.org/10.1007/s00402-007-0547-9>
- [22] Ha, A.S., Petscavage-Thomas, J.M. and Tagoylo, G.H. (2014) Acromioclavicular Joint: The Other Joint in the Shoulder. *American Journal of Roentgenology*, **202**, 375-385. <https://doi.org/10.2214/AJR.13.11460>
- [23] Kiel, J., Taqi, M. and Kaiser, K. (2018) Acromioclavicular Joint Injury. StatPearls Publishing LLC, Saint Petersburg.
- [24] Renfree, K.J. and Wright, T.W. (2003) Anatomy and Biomechanics of the Acromioclavicular and Sternoclavicular Joints. *Clinics in Sports Medicine*, **22**, 219-237. [https://doi.org/10.1016/S0278-5919\(02\)00104-7](https://doi.org/10.1016/S0278-5919(02)00104-7)
- [25] Mazzocca, A.D., Conway, J E., Johnson, S., *et al.* (2004) The Anatomic Coracoclavicular Ligament Reconstruction. *Operative Techniques in Sports Medicine*, **12**, 56-61. <https://doi.org/10.1053/j.otsm.2004.04.001>
- [26] Nicholas, S.J., Lee, S.J., Mullaney, M.J., *et al.* (2007) Clinical Outcomes of Coracoclavicular Ligament Reconstructions Using Tendon Grafts. *The American Journal of Sports Medicine*, **35**, 1912-1917. <https://doi.org/10.1177/0363546507304715>
- [27] Tauber, M., Gordon, K., Koller, H., *et al.* (2009) Semitendinosus Tendon Graft versus a Modified Weaver-Dunn Procedure for Acromioclavicular Joint Reconstruction in Chronic Cases: A Prospective Comparative Study. *The American Journal of Sports Medicine*, **37**, 181-190. <https://doi.org/10.1177/0363546508323255>