



Chitin Bodies Vs Teeth of Hookworm

Forman Erwin Siagian ^{a*}

^a Department of Parasitology, Faculty of Medicine, Universitas Kristen Indonesia, Jakarta, Indonesia.

Author's contribution

The sole author designed, analyzed, interpreted and prepared the manuscript.

Article Information

DOI: 10.9734/AJRIZ/2024/v7i2143

Open Peer Review History:

This journal follows the Advanced Open Peer Review policy. Identity of the Reviewers, Editor(s) and additional Reviewers, peer review comments, different versions of the manuscript, comments of the editors, etc are available here: <https://www.sdiarticle5.com/review-history/114093>

Mini-review Article

Received: 01/01/2024

Accepted: 02/03/2024

Published: 04/03/2024

ABSTRACT

Aims: To differentiate morphologically and functionality of chitin bodies belong to *Necator americanus* (old world hook worm) vs. 2 pair of teeth belong to *Ancylostoma duodenale* (new world hook worm)

Discussion: Anemia due to hookworms caused by persistent blood loss. Those micro-bleeding occurs due to the attachment to the villi of the host's small intestine in order to facilitate feed on their host's blood. Hookworms use their two pairs of teeth (*A. duodenale*) or cutting plates called chitin bodies (*N. americanus*) to fasten their attachment onto the mucosa and submucosa, where at the same time they secrete a series of biochemically active polypeptides that prevent blood from clotting and suppress the host inflammatory response. Differences in the shape of teeth or similar apparatus in the two species of hookworms that infect humans play a role in the occurrence of persistent minor bleeding that causes anemia and this also depend on the number of hookworms invaded the host.

Conclusion: chitin bodies of *N. americanus* causes less bleeding than two pairs of teeth belongs to *A. duodenale*

Keywords: *Necator americanus*; *Ancylostoma duodenale*; anemia; chewing-sucking; piercing-sucking; nematode; zoology.

*Corresponding author: Email: forman.siagian@uki.ac.id;

1. INTRODUCTION

“Hookworms that infect GI tract of human are *N. americanus* and *A. duodenale*” [1-3]. “Globally, the most prevalent hookworm species between these two was *N. americanus* while on the other hand, the proportion of people with *Ancylostoma* spp infection was significantly lower” [2]. “They generally reside in the small intestine of infected individuals where they attach themselves to the villi and feed on host blood” [3]. “Among individuals with inadequate iron intake and high physiological demands, this blood loss can result in anemia” [1-3]. The aim of this short review article is to give insight regarding the differentiation morphologically and functionality of chitin bodies belong to *N. americanus* (old world hook worm) vs. two pair of teeth belong to *A. duodenale* (new world hook worm).

2. EPIDEMIOLOGY

“Hookworm belongs to the group called soil-transmitted helminths (STH) and is one of the most prevalent roundworm of humans” [2]. “Infection commonly occur in areas where soil contamination is common, e.g., due to the practice of human feces are used as fertilizer or where defecation onto soil happens, or eating raw vegetables, absence of regular wearing of shoes/sandals/boots while doing activity in the soil and poor hand washing habit, absence of proper utilization of latrines with the contribution of absence of deworming” [1-4].

“Pruritus and in combination with a localized rash are common initial signs of infection which the vulnerable individual affected not realized” [5]. “These symptoms occur when the larvae penetrate the skin” [1,2]. “A mild infection may cause no symptoms” [2,5]. “A person with a moderate to heavy infection may experience abdominal pain, diarrhea, loss of appetite, weight loss, fatigue and anemia” [1-5]. “Hookworms cause injury through intestinal blood loss that results from attachment of adult parasites to the mucosa and submucosa of the small intestine with resultant rupture of capillaries in the mucosa and arterioles in the submucosa” [6]. The next section will reveal the morphologically differentiation between both species of human intestinal infecting hookworms.

3. DIFFERENCES IN MORPHOLOGY AND FUNCTIONALITY

In the case of common nematodes, their bodily appearance is round with a certain body cavity

and is sometime described by leading Parasitologists as “tube within a tube.” [7,8] “Its head has an exiguous tiny sense organ, and a mouth opening into a muscular pharynx (throat) where food is pulled in and crushed. This leads into a long simple gut cavity lacking any muscles, and then to an anus near the tip of the body” [7].

There are characteristic differences between *A. duodenale* and *N. americanus*, including the mouthparts. In order to understand the difference, first of all it is better to observe a pathology section of hookworm invasion to the surface of small intestine mucosa.

Fig. 1. explained how chronic and persistent bleeding (hemorrhage) right at the site of its attachment made possible and resulted in an iron-deficiency anemia that happened chronically [10], accompanied with serum and gastrointestinal protein loss [11], and even induced unnoticed minimal intestinal inflammation that somehow promotes their own survival, by creating certain local immunoregulatory milieu thanks to their excretory/secretory products [12], but on the other hand, paradoxically also benefits the host by protecting against the onset of many inflammatory diseases [13].

“Morphologically, there is difference between both species of hookworm while have contact with its predilection site” [14]. The buccal capsule of an adult *A. duodenale* has fully developed teeth to facilitate attachment to mucosa [15], whereas mature *N. americanus* has two ventrally located chitin bodies [1,7,16], semi-lunar in shape [16] so called cutting plates instead which help to become anchored at the host's intestinal wall [17]. Strong esophageal muscles ensure and creates negative pressure of suction in the region of buccal capsule. Roggen [18] in his classic manuscript mentioned if a nematode requires a higher suction pressure, this worm can accomplish that suction with its own internal cylindrical pharynx by way of reducing the lumen diameter.

Using their muscular buccal capsule, the adult worms attach themselves to the mucosal and sub mucosal layer [19] of the upper most portion of small intestine, including the lower part of the duodenum - where Kato et al. [20] during routine upper gastrointestinal endoscopy was directly found (detected and retrieved) from the duodenum with biopsy forceps during upper gastrointestinal endoscopy and so he alerted all internists who was performing the endoscopy to

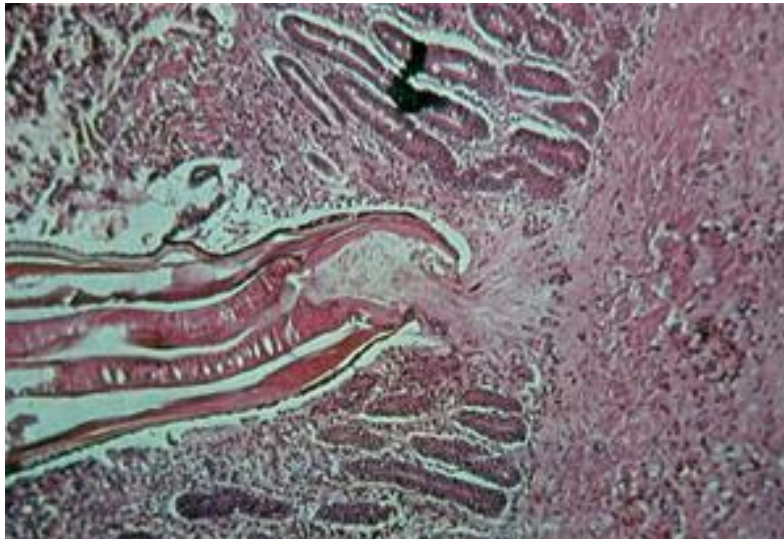


Fig. 1. Highly magnified histo-pathologic sagittal section presented hookworm that attached deep to the intestinal mucosa and feed on blood from lacerated capillaries. Hookworms use their two pairs of teeth (*A. duodenale*) or cutting plates called chitin bodies (*N. americanus*) to fasten their grip onto the mucosa and submucosa, where they secrete a battery of biochemically active polypeptides that prevent blood from clotting and downregulate the host inflammatory response. ([9], with modification).

analyze carefully the mucosal surface even in the distal duodenum at whenever parasitic disease is suspected but is hard to diagnose because of a limited number of eggs in feces.

In addition to duodenum [20,21], jejunum [22], and terminal ileum [23] are also its favorite predilection, but especially in the region of distal jejunum [22]. According to Wei et al [24] Most hookworms frequently appeared between the distal duodenum and the distal jejunum. The localization of these hookworms was determined topographically by Rep [21] that found "*N. americanus* worms were concentrated in the duodenum and jejunum, whereas *A. duodenale* worms rather prefer the jejunum and proximal ileum. Some preference of hookworms for the anti-mesenteric site of the intestinal wall was found. The relative distance between adjoining worms in the observed hookworm populations was 3.8 cm on the average for *Necator* and 5.5 cm for *Ancylostoma*".

Adult worms use their teeth or cutting plates that line their buccal capsule to get fixed into the host's intestinal mucosa and sub mucosa [7,10,12], even to a deeper portion (serosa) [25]. During the process of invasion, adult hookworms which secrete biochemically vigorous peptides that promote the lust to blood feeding [19], penetrate actively until it reaches the arterioles and venules along the luminal surface of the

intestine [26] causing these vital micro-vasculatures to rupture [20-24]; but in the same time, hookworm possess anticoagulant substances that are secreted to prevent blood clotting to the shed of blood flowing from the wound [12,27].

"The differentiation of mouthparts of *A. duodenale* and *N. americanus* is prominent. Species of *Ancylostoma* have buccal cavities with sharp teeth with the ventral margin of the stoma armed by one (*A. braziliense*), two (*A. duodenale*), or three (*A. caninum* and *A. tubaeforme*) pairs of very sharp teeth" [28]. "In case of *A. duodenale*, they use all four teeth to attach to surface of the lumen of the small intestine" [21,27,28]. Young and adult worms feed on blood from the walls of the host's intestine by attaching to the intestinal lining via their sharp buccal cavity teeth [7,11,12], which they also use to break open small blood vessels so that they can suck the blood from them. This method of food obtaining sometime called "chewing and sucking apparatus". "The mucosal piercing process, which is fully mechanical, facilitated by quickly spinning, body-pushing movement that caused piercing happened within a few seconds (mimicking electric piercing apparatus and on magnification perhaps appeared as a frightening piercing episodes)" [29].

On the other hand, *N. americanus* have chitin bodies, an apparatus similar to a stylet, a primitive piercing, tube-like mouthpart which is sharp that act like a cutting plate and can be driven into prey parts [21]. Chitin bodies functions as a tool to aid in mechanical digestion or pierce their target by cutting through layer by layer and followed by sucking when feeding; this condition was well described by Barakat et al. [29] as the worm biological enterprises were taped *in vivo* real-time, and those activates revealed a series of condition including (1) mucosal invasion through a vigorous grip by its teeth or chitin bodies, (2) swift piercing operation, (3) recurrent bloodsucking activities, and (4) its effect to the gut mucosal appearance during the stages of feeding, digestion, and excretion in male and female worms. Worm blood feeding occurs after quick mucosal piercing, with blood loss being aggravated by a repeated feeding behavior. This method of obtaining their meal sometime called “piercing and sucking apparatus”.

However, the blessing in disguise of this worm's greedy character can actually be used for treatment with a unique approach as is conducted by Bi et al. [30] which tried a non-traditional therapeutic approach for a sustainable

solution to manage parasite infections. In their study, they tried to elaborate a novel approach of therapy using value-added probiotics-producing antiparasitic RNA interference (RNAi) molecules against a vital hookworm (*Ancylostoma* sp.) enzyme, astacin-like metalloprotease Ac-MTP-1. A new gut delivery RNAi vector was designed to produce double-stranded RNA (dsRNA) against the target to be delivered by feeding (administered through the oral route) with a probiotic *Lactococcus lactis* that when administered in endemic areas can potentially be used to control the spread of infection by interrupting the life cycle of hookworm. The results are very promising where the engineered probiotics colonizing the gut (soon after consumed), and at the time the colonizing engineered probiotics accidentally devoured by the hookworm, it unleashed the dsRNA that which knocked down the target worm by RNAi interfering with their moulting and tissue migration which marked by (1) diminished initial penetration of the larvae into the gut lining (up to 70%), followed by (2) an abatement of migration ability to the critical organs (up to 50%). The damage to nearby organs by the hookworm in mouse models, e.g. to the liver and the kidneys (as measured by enzymes quantity trapped in the blood) was fully reversed when the worms

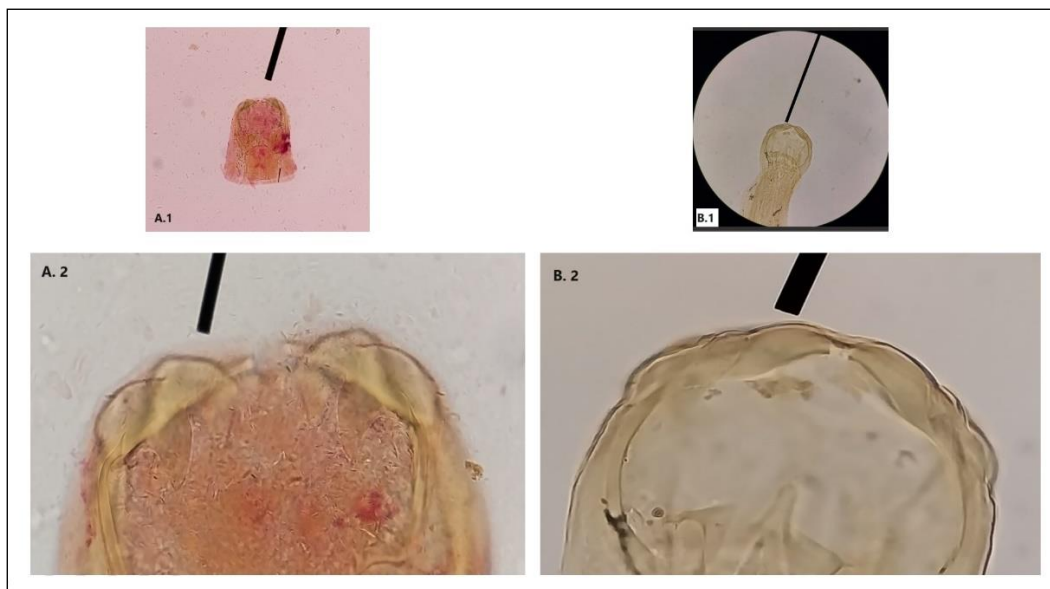


Fig. 2. (A) head of *A. duodenale* (A.1) in total 100x magnification picture taking with a phone cell using 2x optical zoom, (A.2) two pair of teeth of *A. duodenale* in total 400x magnification, picture taking with a phone cell using 2.5x optical zoom. (B) head of *N. americanus* (B.1) in total 100x magnification, picture taking using a phone cell with 1x optical zoom, (B.2) chitin bodies of *N. americanus* in total 400x magnification, picture taking with a phone cell using 2.6x optical zoom. All slides of hookworm and microscope (Olympus CX21 LED) courtesy of Dept. of Parasitology, Faculty of Medicine, Universitas Kristen Indonesia, Jakarta-Indonesia

were pre fed with the genetically engineered *L. lactis* before the parasite challenge. This state of the art method of parasite control when extended to other hookworms, *A. duodenalis* and *A. ceylanicum* can aggrandize the efficacy of the pharmacologically anthelmintic if combined with them.

4. WHICH ONE MAKES BLEEDING MORE PROFUSE AND WHY?

Theoretically, comparison of bleeding/injuries caused by four teeth (2 pairs) of *A. duodenale* [31] compared to chitin bodies (*N. americanus*) where they inject excretory/secretory (ES) products into the mucosa [32], the bleeding will be more prominent due to chitin bodies. But report from Australia and some other studies debunked this theory [2,26,30,31,33]. Once worms reach the small intestines, they attach to the mucosa by ingesting a tissue plug into their mouths and commence feeding on blood. They have voracious appetites and individual adult *N. americanus* worms may consume 0.03 ml blood per day [17], while those of *A. duodenale* may take up to 0.26 ml blood per day [30,31]. Blood loss from the host may result in a profound iron-deficiency anemia and hyperproteinemia [33].

Hookworms, especially *A. duodenale*, materialize to be imprudent/wasteful feeders because not all blood consumed is further digested and absorbed [34,35]. Ashamedly, much more blood being lost than is actually ingested by the worm, but on contrary some is apparently used for respiration [30] and only passes through the hookworm but rapidly degrades in the host's intestines resulting in unexplained black melena (tarry feces) especially in the more vulnerable elderly sub population [36,37]. The condition of rapid passage of the blood inside the hookworm confirmed by the case report conducted by Tiremo and Shibesi [38] which use an Esophagogastroduodenoscopy to diagnose of hookworm disease in a 61 years old farmer with severe iron deficiency anemia. They revealed multiple small translucent, blood-filled hookworms.

Actually, most blood loss is a result of leakage around the hookworm attachment site [1,38] rather than direct ingestion by the worm. Blood loss is further exacerbated by villous injuries and intestinal lacerations [39] as active blood seeking hookworms move to new feeding sites from time to time [17,21,26], secreting proteolytic enzymes

[12] and anticoagulants, and leaving microscopic ulcers. "Both (enzymes and anticoagulant) inhibits the clotting of human plasma and promotes fibrin clot dissolution. This anticoagulant activity is attributable to a 36,000 Dalton proteolytic enzyme. The protease can degrade fibrinogen into five smaller polypeptides that intrinsically have anticoagulating properties, covert plasminogen to a mini-plasminogen-like molecule, and hydrolyze a synthetic peptide substrate with specificity for elastolytic enzymes. It is hypothesized that the parasite uses this enzyme to prevent blood clotting while feeding on villous capillaries" [37].

In the end, from all academic data discussed previously, there are at least three reason why *A. duodenale* produce more obvious anemia compared to *N. americanus*; and are described as follows:

1. Fully developed mature *A. duodenale* worms are bigger in size than *N. americanus* and produce more eggs (25,000 versus 10,000/female/day) and therefore need more blood, and in order to fulfill that need, they cause more blood loss from the host,
2. The shape of the teeth apparently causes more bleeding than chitin bodies because the teeth can penetrate deeper layers, where there are capillaries that supply the mucosa and submucosa while even though chitin bodies are actually sharp but are less supportive in causing bleeding because they are used to slice, layer by layer, so the speed of reaching where the blood vessels also limited,
3. Infections involving <100 Necator are frequently mild whereas >100 worms produce more damage and >1,000 may be fatal. Fewer Ancylostoma cause greater disease because they suck more blood, 100 worms may cause severe disease.

5. CONCLUSION

In addition to differences in the method of invasion of the intestinal surface, it turns out that the new world hookworm, *A. duodenale* cause more bleeding than *N. americanus* and the severity of the hemorrhage also depend on other factors such as the number of hookworm invaded the host or co-infection with other soil transmitted helminths.

COMPETING INTERESTS

Author has declared that no competing interests exist.

REFERENCES

1. Ghodeif AO, Jain H. Hookworm. In: StatPearls [Internet]. Treasure Island (FL): StatPearls Publishing; 2024. Available: <https://www.ncbi.nlm.nih.gov/books/NBK546648/> [Accessed on: 2023 Jun 15].
2. Clements ACA, Addis Alene K. Global distribution of human hookworm species and differences in their morbidity effects: a systematic review. *The Lancet. Microbe.* 2022;3(1):e72-e79. Available: [https://doi.org/10.1016/s2666-5247\(21\)00181-6](https://doi.org/10.1016/s2666-5247(21)00181-6)
3. Smith JL, Brooker S. Impact of hookworm infection and deworming on anemia in non-pregnant populations: a systematic review. *Trop Med Int Health.* 2010;15(7):776-95. Available: <https://doi.org/10.1111/j.1365-3156.2010.02542.x>
4. Hailu T, Mulu W, Abera B. Prevalence and determinant factors of hookworm infection among school age children in Jawe district, NorthWest Ethiopia. *Afr Health Sci.* 2019; 19(3):2439-2445. Available: <https://doi.org/10.4314/ahs.v19i3.18>
5. Hotez PJ, Bethony J, Bottazzi ME, Brooker S, Buss P. Hookworm: The great infection of mankind. *PLoS Med.* 2005;2(3):e67. Available: <https://doi.org/10.1371/journal.pmed.0020067>
6. Hotez PJ, David Diemert D. Chapter 66 - Hookworm Infection, in Barrett ADT, Stanberry LR (Eds). *Vaccines for Biodefense and Emerging and Neglected Diseases*, Academic Press. 2009;1365-78. Available: <https://doi.org/10.1016/B978-0-12-369408-9.00066-4> ISBN 9780123694089.
7. Basyoni MM, Rizk EM. Nematodes ultrastructure: Complex systems and processes. *J Parasit Dis.* 2016;40(4):1130-1140. Available: <https://doi.org/10.1007/s12639-015-0707-8>
8. Shah MM, Mahamood M. Introductory Chapter: Nematodes - A Lesser Known Group of Organisms [Internet]. *Nematology - Concepts, Diagnosis and Control*. InTech; 2017. Available: <http://dx.doi.org/10.5772/intechopen.68589>
9. Anonymous. Parasites – Hookworm: Disease. Centers for Disease Control and Prevention; 2013. Available: <https://www.cdc.gov/parasites/hookworm/disease.html>
10. Li B, Chen S, Cui X, Dai M, Meng W, Wu Q, Sheng H. Chronic Hemorrhagic Anemia Caused by Hookworm Infection: A Case Report. *Acta Parasitol.* 2023;68(1):288-92. Available: <https://doi.org/10.1007/s11686-022-00653-y>.
11. Gupta MC, Basu AK, Tandon BN. Gastrointestinal protein loss in hookworm and roundworm infections. *Am J Clin Nutr.* 1974;27(12):1386-9. Available: <https://doi.org/10.1093/ajcn/27.12.1386>
12. Abuzeid AMI, Zhou X, Huang Y, Li G. Twenty-five-year research progress in hookworm excretory/secretory products. *Parasit Vectors.* 2020;13(1):136. Available: <https://doi.org/10.1186/s13071-020-04010-8>
13. Ferreira IB, Pickering DA, Troy S, Croese J, Loukas A, Navarro S. Suppression of inflammation and tissue damage by a hookworm recombinant protein in experimental colitis. *Clin Transl Immunology.* 2017;6(10):e157. Available: <https://doi.org/10.1038/cti.2017.42>
14. Hoagland KE, Schad GA. *Necator americanus* and *Ancylostoma duodenale*: life history parameters and epidemiological implications of two sympatric hookworms of humans. *Exp Parasitol.* 1978;44(1):36-49. Available: [https://doi.org/10.1016/0014-4894\(78\)90078-4](https://doi.org/10.1016/0014-4894(78)90078-4)
15. Aziz MH, Ramphul K. *Ancylostoma*. [Updated 2023 Apr 10]. In: StatPearls [Internet]. Treasure Island (FL): StatPearls Publishing; 2024. Available: <https://www.ncbi.nlm.nih.gov/books/NBK507898/>
16. Chang T, Jung BK, Sohn WM, Hong S, Shin H, Ryoo S, Lee J, Lee KH, Khieu V, Huy R, Chai JY. Morphological and Molecular Diagnosis of *Necator americanus* and *Ancylostoma ceylanicum* Recovered from Villagers in Northern Cambodia. *Korean J Parasitol.* 2020;58(6):619-625. Available: <https://doi.org/10.3347/kjp.2020.58.6.619>

17. Mehlhorn H. *Necator americanus*. In: Mehlhorn, H. (eds) *Encyclopedia of Parasitology*. Springer, Berlin, Heidelberg; 2016.
Available:https://doi.org/10.1007/978-3-662-43978-4_2077
18. Roggen DR. Functional Morphology of the Nematode Pharynx. II. Spherical Bulbs. *Nematologica* 1979;25(1): 127-135.
Available:<https://doi.org/10.1163/187529279X00451> Web.
19. Brooker S, Bethony J, Hotez PJ. Human hookworm infection in the 21st century. *Adv Parasitol*. 2004;58:197-288.
Available:[https://doi.org/10.1016/S0065-308X\(04\)58004-1](https://doi.org/10.1016/S0065-308X(04)58004-1).
20. Kato T, Kamoi R, Iida M, Kihara T. Endoscopic diagnosis of hookworm disease of the duodenum. *J Clin Gastroenterol*. 1997;24(2):100-2.
Available:<https://doi.org/10.1097/00004836-199703000-00012>
21. Rep BH. The topographic distribution of *Necator americanus* and *Ancylostoma duodenale* in the human intestine. *Trop Geogr Med*. 1975 Jun;27(2):169-76.
22. Layrisse M, Blumenfeld N, Carbonell L, Desenne J, Roche M. Intestinal Absorption Tests and Biopsy of the Jejunum in Subjects with Heavy Hookworm Infection. *Am J Trop Med Hyg*. 1964;13:297-305.
Available:<https://doi.org/10.4269/ajtmh.1964.13.297>
23. Chandak RJ, Thakur A, Sud S, Mishra B, Dogra V. Hookworm in the terminal ileum: a common cause of severe anemia residing in a rare location. *Journal of Microbiology and Infectious Diseases*. 2017;7(2):98-100.
Available:<https://doi.org/10.5799/ahinjs.02.2017.02.0262>
24. Wei KY, Yan Q, Tang B, Yang SM, Zhang PB, Deng MM, Lü MH. Hookworm Infection: A Neglected Cause of Overt Obscure Gastrointestinal Bleeding. *Korean J Parasitol*. 2017;55(4):391-398.
Available:<https://doi.org/10.3347/kjp.2017.55.4.391>.
25. Spraker TR, DeLong RL, Lyons ET, Melin SR. Hookworm enteritis with bacteremia in California sea lion pups on San Miguel Island. *J Wildl Dis*. 2007;43(2):179-88.
Available:<https://doi.org/10.7589/0090-3558-43.2.179>
26. Thomas V, Harish K, Tony J. Hookworm infection: does it cause overt intestinal bleeding? *Gastrointestinal Endoscopy*. 2006;63(4): 736.
Available:<https://doi.org/10.1016/j.gie.2005.11.013>
27. Hotez PJ, Cerami A. Secretion of a proteolytic anticoagulant by *Ancylostoma hookworms*. *J Exp Med*. 1983;157(5): 1594-603.
Available:<https://doi.org/10.1084/jem.157.5.1594>
28. Marchiondo AA, Cruthers LR, Fourie JJ (eds). Chapter 2 – Nematoda in Parasiticide Screening, Academic Press. 2019;2:135-335,
Available:<https://doi.org/10.1016/B978-0-12-816577-5.00007-7>
ISBN: 9780128165775
29. Barakat M, Ibrahim N, Nasr A. In vivo endoscopic imaging of ancylostomiasis-induced gastrointestinal bleeding: Clinical and biological profiles. *Am J Trop Med Hyg*. 2012;87(4):701-5.
Available:<https://doi.org/10.4269/ajtmh.2012.12.0018>.
30. Anonymous. *Ancylostoma/Necator*. Available:<https://www.parasite.org.au/parasite/text/ancylostoma-necator-text.html>
31. Ronquillo AC, Puelles LB, Espinoza LP, Sánchez VA, Luis Pinto Valdivia J. *Ancylostoma duodenale* as a cause of upper gastrointestinal bleeding: a case report. *Braz J Infect Dis*. 2019;23(6):471-473.
Available:<https://doi.org/10.1016/j.bjid.2019.09.002>
32. Logan J, Pearson MS, Manda SS, Choi YJ, Field M, Eichenberger RM, Mulvenna J, Nagaraj SH, Fujiwara RT, Gazzinelli-Guimaraes P, Bueno L, Mati V, Bethony JM, Mitreva M, Sotillo J, Loukas A. Comprehensive analysis of the secreted proteome of adult *Necator americanus* hookworms. *PLoS Negl Trop Dis*. 2020; 14(5):e0008237.
Available:<https://doi.org/10.1371/journal.pntd.0008237>
33. Albonico M, Stoltzfus RJ, Savioli L, Tielsch JM, Chwaya HM, Ercole E, Cancrini G. Epidemiological evidence for a differential effect of hookworm species, *Ancylostoma duodenale* or *Necator americanus*, on iron status of children. *Int J Epidemiol*. 1998;27 (3):530-7.
Available:<https://doi.org/10.1093/ije/27.3.530>
34. Chapman PR, Giacomini P, Loukas A, McCarthy JS. Experimental human hookworm infection: a narrative historical

- review. PLoS Negl Trop Dis. 2021 Dec 9;15(12):e0009908.
Available:<https://doi.org/10.1371/journal.pntd.0009908>
35. Loukas A, Hotez P, Diemert D. Hookworm infection. Nat Rev Dis Primers. 2016;2:16088.
Available:<https://doi.org/10.1038/nrdp.2016.88>
36. Tariq M, Muzammil SM, Shaikh FA, Pal KM. Hookworm infestation as a cause of melena and severe anaemia in farmer. J Pak Med Assoc. 2017 Feb;67(2):327-329.
37. Kuo YC, Chen WC, Chih JC, Tsang EW, Wen HC, Shou CS. Endoscopic diagnosis of hookworm infection that caused anemia in an elderly person. International Journal of Gerontology. 2010;9:199-201.
Available:<https://doi.org/10.1016/J.IJGE.2010.11.008>
38. Tiremo SN, Shibeshi MS. Endoscopic Diagnosis of Hookworm Disease in a Patient with Severe Iron Deficiency Anemia: A Case Report. Int Med Case Rep J. 2023;16:841-845.
Available:<https://doi.org/10.2147/IMCRJ.S443625>
39. Alkazmi LM, Dehlawi MS, Behnke JM. The effect of the hookworm *Ancylostoma ceylanicum* on the mucosal architecture of the small intestine in hamsters. J Helminthol. 2006;80(4):397-407.
Available:<https://doi.org/10.1017/joh2006372>

© Copyright (2024): Author(s). The licensee is the journal publisher. This is an Open Access article distributed under the terms of the Creative Commons Attribution License (<http://creativecommons.org/licenses/by/4.0>), which permits unrestricted use, distribution, and reproduction in any medium, provided the original work is properly cited.

Peer-review history:

The peer review history for this paper can be accessed here:
<https://www.sdiarticle5.com/review-history/114093>