



# **A Comprehensive Review of COVID-19 Vaccines, Adverse Reactions, and the Imperative of Early Diagnosis**

**Swetha J. <sup>a++</sup>, Karthikeyan K. <sup>b#</sup>, Shanmugasundaram P. <sup>at</sup> and Balaji P. <sup>c†\*</sup>**

<sup>a</sup> School of Pharmaceutical Science-VIATAS, Tamil Nadu, India.

<sup>b</sup> Department of Pharmacy Practice, School of pharmaceutical science-VISTAS, Tamil Nadu, India.

<sup>c</sup> Department of Pharmacology, School of Pharmaceutical Science-VISTAS, Tamil Nadu, India.

## **Authors' contributions**

*This work was carried out in collaboration among all authors. All authors read and approved the final manuscript.*

## **Article Information**

### **Open Peer Review History:**

This journal follows the Advanced Open Peer Review policy. Identity of the Reviewers, Editor(s) and additional Reviewers, peer review comments, different versions of the manuscript, comments of the editors, etc are available here: <https://www.sdiarticle5.com/review-history/113624>

**Case Study**

**Received: 20/12/2023**

**Accepted: 28/02/2024**

**Published: 04/03/2024**

## **ABSTRACT**

Bullous pemphigoid (BP) is a rare autoimmune subepidermal blistering disorder and is defined by the existence of circulating G immunoglobulins (IgG) against basement membrane antigens BP180 and BP230, the immunobullous skin disorder characteristically presents with intense bullae and intense generalized pruritis, where the immune system attacks a thin layer of tissue below the outer layer of skin. Most of the BP cases are due to autoantibodies against proteins arranged at the dermal-epidermal junction, BP is also caused by systemic medications. Either the presence of certain triggering factors in the covid vaccine or the dissimilarity between the vaccine structure and the basement membrane antigens, had activated the B-cell immunity and therefore the production of antibodies, which is the main cause behind the activation of BP. A classic case of this condition

<sup>++</sup> Student;

<sup>#</sup> HOD;

<sup>†</sup> Dean;

<sup>‡</sup> Professor;

\*Corresponding author: E-mail: 11116swethajayaraman@gmail.com;

is presented here to highlight and to create awareness about the symptoms occurred after COVID-19 vaccination. A 41-year-old female patient presented with BP caused after the administration of 1<sup>st</sup> dose of covid vaccine.

**Keywords:** Allergy; bullous pemphigoid; covishield vaccine allergy; autoimmune subdermal blistering disorder; rashes.

## 1. INTRODUCTION

This topic deals about the adverse event of Bullous Pemphigoid which was triggered due to allergic reaction to covid vaccine caused after administration of the 1<sup>st</sup> dose of covid vaccine. In 2019, the world faced the rampant coronavirus (COVID-19) which led to the abnormal impact on the overall health and the global economy of 411 trillion. In 2020, population with confirmed cases of covid was 235 million, with approximately 4.8 million deaths [1]. "COVID-19 has rocketed to destructive proportions with 50 crore confirmed cases globally as of April 2022" [2]. "It started as an outbreak in Wuhan, China and was declared a pandemic by World Health Organization (WHO) on March 11, 2020. As of 11th October 2021, 237, 383, 711 confirmed cases of COVID-19, and 4,842,716 deaths have been reported to WHO" [3]. "Various treatment options and strategies were undertaken to curb its vigorous spread through social distancing, sanitizing, use of drugs such as antivirals, antimalarials, steroids, cytokine inhibitors, monoclonal antibodies and convalescent plasma therapy were proposed as the remedy of COVID-19. However, none of them have been found to be effective in curing the disease due to the continuous mutation of the coronavirus. So, the invention of the vaccine was the main goal among the scientists. COVID-19 vaccine is the fastest developed vaccine in history with the Pfizer-BioNTech vaccine being approved for emergency use on 2<sup>nd</sup> December 2020 in UK just a year after the first case was reported in China. As of September 2021, 37 vaccines have completed Phase III trial and 22 vaccines have been approved for use by at least one country" [4]. "Covishield vaccine is one of the recombinant vaccines developed by Oxford University and manufactured by Serum Institute of India. Various adverse events following immunization has been reported worldwide with the development of COVID-19 vaccine". [5] In June 2021, the first side effect due to Covishield 1<sup>st</sup> dose was reported in a 22-year-old girl, the adverse reaction of the vaccine caused the girl's brain dead with severe neurological complications, started with the side effect of

chronic headache, then slowly with the formation of clot in the brain [6]. "A study was conducted using COVID Symptom Study app in UK and the report showed the incidence of local and systemic reactions as 58.7% and 33.7% respectively following the first dose of ChAdOx1 nCoV-19 vaccine" [7]. "Following the first dose of the Pfizer BioNTech vaccination, injection site reactions were reported in 65.4% and systemic reactions were reported in 48%, whereas 73.9% injection site reactions and 51.7% systemic reactions were reported after the first dose of the covid vaccine. There is a lack of sufficient evidence regarding the safety profile of these vaccines" [8]. Insufficient evidences led to the vaccine hesitancy in public. The following example illustrates the adverse effects caused due to the 1<sup>st</sup> dose of ChAdOx1 nCoV-19 (Covishield vaccine) which is an adenovirus vector vaccine.

## 2. CASE REPORT

A 41-years-old female patient visited the dermatologist in the initial stage with maculopapular rashes, itching, watery discharge, blisters. She was treated with steroids. It got subsided, but after leaving the medicines, the same symptoms got worsted by reoccurring all over the body with throat pain, fever, rigors. The above symptoms were started after taking 1<sup>st</sup> dose of covid vaccine (COVISHIELD). Then she was admitted to Isabel's Hospital-Mylapore, Chennai in general department. The patient was conscious, oriented, and febrile, according to her general examination.

The pulse rate, blood pressure and vital signs appear to be normal. The systemic examination revealed that all systems were operating normally.

Table 1 shows the hematological reports of patient which showed microcytic Hypo-chromic anemia -Elliptocytes (RBC with elliptical shape), Anis poikilocytosis (RBC with different sizes and shapes such as MHA and Elliptocytes), Neutrophilia (Increased production of neutrophils), Eosinophilia (Increased production of eosinophils). The ECG reports were normal.

**Table 1. Patient hematological investigations**

CBC Test	Abnormal value	Normal value
Hb	10.6g%	M:13-18g%; F:11.5-16.5g%
RBC COUNT	5.3 million/cmm	M:4.5-6.5 10 <sup>6</sup> /cmm; F:3.8-5.8 10 <sup>6</sup> /cmm
PCV	36.5%	M:47-58; F:42-58
NEUTROPHIL%	82%	40-75%
LYMPHOCYTES%	10%	20-45%
EOSINOPHIL%	12%	1-6%
TOTAL WBC	13,300cmm	4000-11000cmm
MCV	68.7fL	79.0-93.3fL
MCH	19.9Pg	27.0-32.0Pg
MCHC	29.0g/dl	32.0-36.0g/dl
PLATELET COUNT	4.13lakhs/cmm	1-4lakh/cmm

Patient was diagnosed as a case of Bullous Pemphigoid triggered due to allergic reaction to covid vaccine.

The patient was treated with- corticosteroids- Inj.methylprednisolone(125mg),Inj.dexamethasone (4mg), immunosuppressant- azathioprine (50mg) orally, anti-histamine- Inj.Pheniramine (2ml), antibiotic- Inj.Meropenem (1g), Inj.Linizolid (600mg). The condition of the patient subsided, the inflammation and allergic symptoms were reduced with the help of above medications, the patient was advised to maintain light diet.

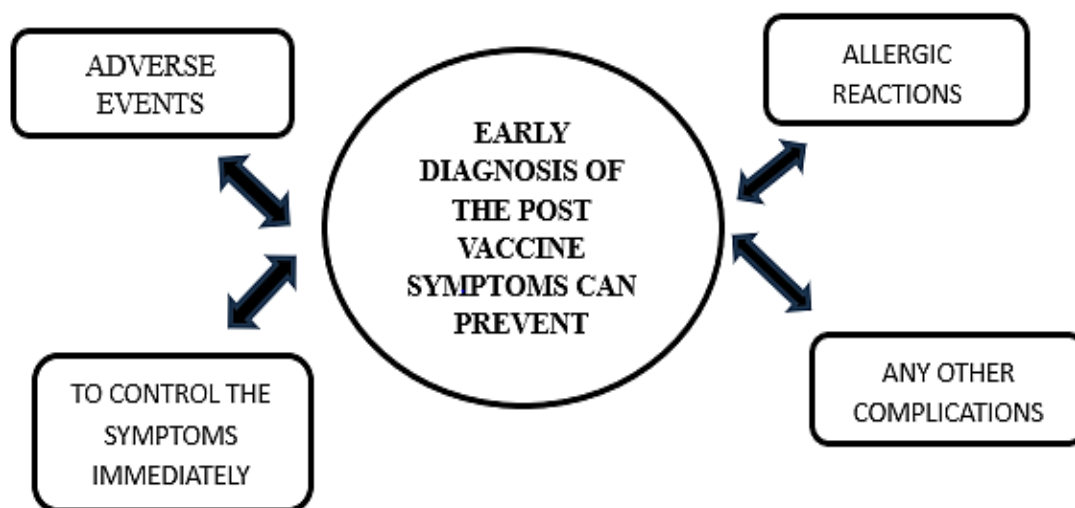
### 3. DISCUSSION

Vaccination is the important and immediate prophylactic measure taken to prevent the further spread of the coronavirus; mostly vaccines cause adverse effects but most of the adverse effects were due to the immunization action such as

fever, allergic reactions as it can activate the B-cell immunity and produce antibodies against the antigens [9]. According to the physicians, though manufactures claimed that Covishield might produce mild reactions, certain pre and post precautions should be taken by the public. The trial population reported mostly mild Covid symptoms, like fever and fatigue [10].

The report given by the government stated that more than 89,000 individuals suffered adverse reactions due to covid vaccines of whom 1,148 individuals died [11].

The above case report is a classic example of autoimmune disease which had been triggered due to the administration of the Covishield vaccine. The patient received the relevant advice regarding therapeutic drug use and was cautioned against vaccination prior medical advice.



**Fig. 1. Early diagnosis of the post vaccine symptoms can prevent**

#### 4. CONCLUSION

Although Covid-19 vaccines can be reported to develop allergic and anaphylactic reactions which is considered as normal, the evidence indicate that vaccines and boosters are effective at helping to prevent serious illness, hospitalization, lethality due to COVID-19. It is necessary that the people should be counseled by the health care providers with adequate information regarding the side effects and advice to report the adverse effects immediately to the physician. Early diagnosis helps the clinician to elude the early symptoms and subsequent complications.

#### CONSENT

As per international standards or university standards, patient(s) written consent has been collected and preserved by the author(s).

#### ETHICAL APPROVAL

As per international standards or university standards written ethical approval has been collected and preserved by the author(s).

#### COMPETING INTERESTS

Authors have declared that no competing interests exist.

#### REFERENCES

1. Global Preparedness Monitoring Board. World Health Organization; Geneva:2020. A World in Disorder. Global Preparedness Monitoring Board Annual Report; 2020. Available:[https://apps.who.int/gpmb/assets/annual-report/GPMB\\_AR\\_2020\\_EN.pdf](https://apps.who.int/gpmb/assets/annual-report/GPMB_AR_2020_EN.pdf) License: CC BY-NC-SA 3.0 IGO. AVAILABLE from:(Google Scholar).
2. WHO. WHO coronavirus disease. WHO. 2021;1. Available from:<https://covid.who.int>
3. Draft Landscape of COVID-19 Candidate Vaccines. 2021. Available:<https://www.who.int/publications/m/items/draft-landscape-of-covid-19-candidate-vaccines>.
4. Vaccines-COVID19 Vaccine Tracker; 2022. Availablefrom:<https://covid19.trackvaccines.org/vaccines/>.
5. Subedi P, Yadav GK, Paudel B, Regmi A, Pyakurel P. Adverse events following the first dose of Covishield (ChAdOx1 nCoV-19) vaccination among health workers in selected districts of central and western Nepal: A cross-sectional study. PLoS One. 2021, Dec 21;16(12):e0260638.
6. Death due to neurological complication- Available:<https://www.thehealthsite.com/news/Delhi>, published on June 22,2021.
7. Vaccine side-effects and SARS-CoV-2 infection after vaccination in users of the COVID Symptom Study app in the UK; a prospective observational study. Menni C, Klaser K, May A, et al. Lancet Infect Dis. 2021;21:939-949.
8. Chapin-Bardales J, Gee J, Myers T. Reactogenicity following receipt of mRNA-Based COVID-19 Vaccines. JAMA-Journal of the American Medical Association; 2021, Apr 5. DOI:10.1001/jama.2021.5374.
9. McNeil MM, Weintraub ES, Duffy J et al. Risk of anaphylaxis after vaccination in children and adults. J Allergy Clin Immunol. 2016;137:868-878.
10. The News India Express publications- Available:<https://www.newsindianexpress.com/cities/Bengaluru/2021/jan/12>
11. 10.Article on How India Failed those who were harmed by the Covid-19 vaccine; 2022. Available:<https://scroll.in/article/1036361/how-india-failed-those-who-were-harmed-by-the-covid-29-vaccine-published-on-November-2nd>, 2022.

© Copyright (2024): Author(s). The licensee is the journal publisher. This is an Open Access article distributed under the terms of the Creative Commons Attribution License (<http://creativecommons.org/licenses/by/4.0>), which permits unrestricted use, distribution, and reproduction in any medium, provided the original work is properly cited.

Peer-review history:

The peer review history for this paper can be accessed here:  
<https://www.sdiarticle5.com/review-history/113624>