



Cardiac Papillary Fibroelastoma, an Unusual Localization in an Asymptomatic Patient with Lieberkühn Type Adenocarcinoma of the Rectum: A Case Report

M. Njie ^{a*}, Y. Toukami ^a, P. M. Mulendele ^a, H. Charif ^a,
Haboub ^{a,b++}, S. Arous ^{a,b++}, G. M. Benouna ^{a,b++},
A. Drighil ^{a,b++} and R. Habbal ^{a,b++}

^a Department of Cardiology P37, Ibn Rochd University Hospital, Casablanca, Morocco.

^b Faculty of Medicine and Pharmacy, Hassan II University of Casablanca, Casablanca, Morocco.

Authors' contributions

This work was carried out in collaboration among all authors. Authors MN, YT and PMM did conception of the clinical case and writing of the manuscript. Author Haboub did course review. All authors read and approved the final manuscript.

Article Information

DOI: 10.9734/CA/2023/v12i4378

Open Peer Review History:

This journal follows the Advanced Open Peer Review policy. Identity of the Reviewers, Editor(s) and additional Reviewers, peer review comments, different versions of the manuscript, comments of the editors, etc are available here: <https://www.sdiarticle5.com/review-history/108690>

Case Study

Received: 10/09/2023

Accepted: 16/11/2023

Published: 18/11/2023

ABSTRACT

Cardiac papillary fibroelastoma is histologically a benign endocardial neoplasm. Though CPF has long been reported as the second most common primary cardiac neoplasm, it has since been pulled ahead of cardiac myxomas, largely due to evolving cardiac imaging modalities. We present a case of CPF originating from an unusual localization; the junction of the posterior mitral valve and

++ Professor;

*Corresponding author: E-mail: malick1njie@hotmail.com;

Cardiol. Angiol. Int. J., vol. 12, no. 4, pp. 352-357, 2023

endocardium of the left ventricle measuring 15 x 20mm, which was detected by a routine pre-evaluation transthoracic echocardiography before chemotherapy and treated by surgical mass excision in an asymptomatic female patient diagnosed with a Lieberkühn type adenocarcinoma of the rectum with a locoregional extension.

Keywords: *Cardiac papillary fibroelastoma; lieberkühn type adenocarcinoma; mass excision.*

1. INTRODUCTION

Cardiac papillary fibroelastoma (CPF) is a rare benign cardiac tumor and location in the left ventricle (LV) is noted in 9% of cases [1]. Cardiac papillary fibroelastoma is histologically a benign endocardial neoplasm. Though CPF has long been reported as the second most common primary cardiac neoplasm, it has since been pulled ahead of cardiac myxomas, largely due to evolving cardiac imaging modalities. While CPF are benign histologically, they have the potential for devastating clinical consequences, transient ischemic attack, stroke, myocardial infarction, syncope, pulmonary and peripheral embolism [2]. CPFs can arise anywhere in the heart, but most are located on the cardiac valves. The aortic valve is the most common site ranging from 37-45% [3]. In contrast, papillary fibroelastomas originating from the mitral valve chordae are extremely rare [4]. We herein present a case of CPF originating from the junction of the posterior mitral valve and endocardium of the left ventricle, which was detected by transthoracic echocardiography and treated by surgical mass excision in a patient diagnosed with Lieberkühn type adenocarcinoma of the rectum.

2. CASE REPORT

A 66-year-old female patient of Moroccan origin with known cardiovascular risk factors: hypertension, type 2 diabetes mellitus, dyslipidemia, and menopause; she was currently under treatment for stage 3 rectal adenocarcinoma with an indication for chemotherapy.

The patient was admitted to the cardiology department of CHU IBN Rochd for a cardiovascular assessment prior to chemotherapy. The patient exhibited no signs of instability, both hemodynamically and circulatory, as well as in terms of respiration or neurology. Furthermore, the cardiovascular examination revealed no abnormalities. An ECG was performed, which did not reveal any electrical anomalies. Additionally, the patient reported two

episodes of brief loss of consciousness that had not been thoroughly investigated two months earlier.

The 2D transthoracic echocardiography (TTE) performed revealed an oval-shaped, hyperechoic mass at the atrioventricular junction, affecting the posterior mitral valve leaflet on its ventricular aspect measuring 14 x 19mm without obstruction of mitral valves during diastolic heart filling (Fig. 1).

A cardiac magnetic resonance imaging (MRI) was conducted and confirmed the presence of a small sessile mass attached to the ventricular side of the posterior mitral valve leaflet, measuring 20x15 mm with a broad base, displaying low T2 signal intensity and isointensity on T1. Radiologically, this presentation aligns with a fibroelastoma (Fig. 2).

Furthermore, the patient exhibits preserved biventricular function with an ejection fraction of 62% for the left ventricle and 60% for the right ventricle.

As for the remaining complementary examinations, a thoracic CT scan was performed as part of the rectal adenocarcinoma staging, which did not reveal any thoracic metastases or other anomalies. An abdominopelvic MRI showed an irregular tumor-related thickening of the lower rectum in contact with the internal sphincter without external sphincter invasion or involvement of the levator ani planes. Additionally, there was thickening of the gastric antrum, suggestive of pan-gastritis and Forrest stage 3 pre-pyloric ulcers.

Histopathological examination of the lesion revealed a moderately differentiated, ulcerated, and invasive Lieberkühn-type adenocarcinoma of the rectum.

Furthermore, the patient's biological profile indicates microcytic hypochromic anemia with a hemoglobin level of 8.8 g/dL, disrupted lipid profile (total cholesterol 2.29 g/L, LDL-cholesterol 1.59 g/L, HDL-cholesterol 0.42 g/L, and

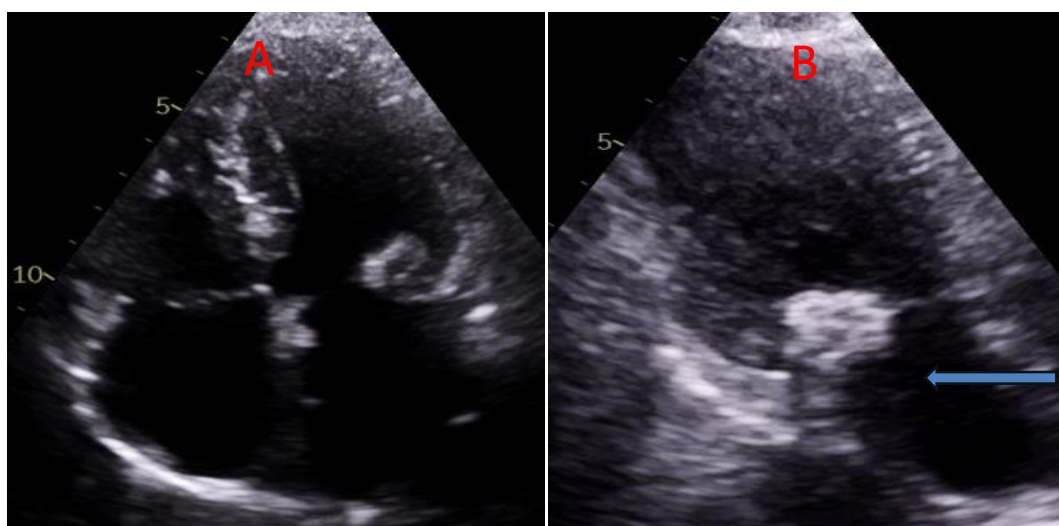


Fig. 1. 2D Transthoracic echocardiography: A- Apical 4 chambers' view: showing an oval-shaped, hyperechoic mass at the atrioventricular junction, B- Apical 2 chambers view: cardiac mass largely depending on the posterior mitral valve leaflet on its ventricular aspect measuring 14 x 19mm (blue arrow)

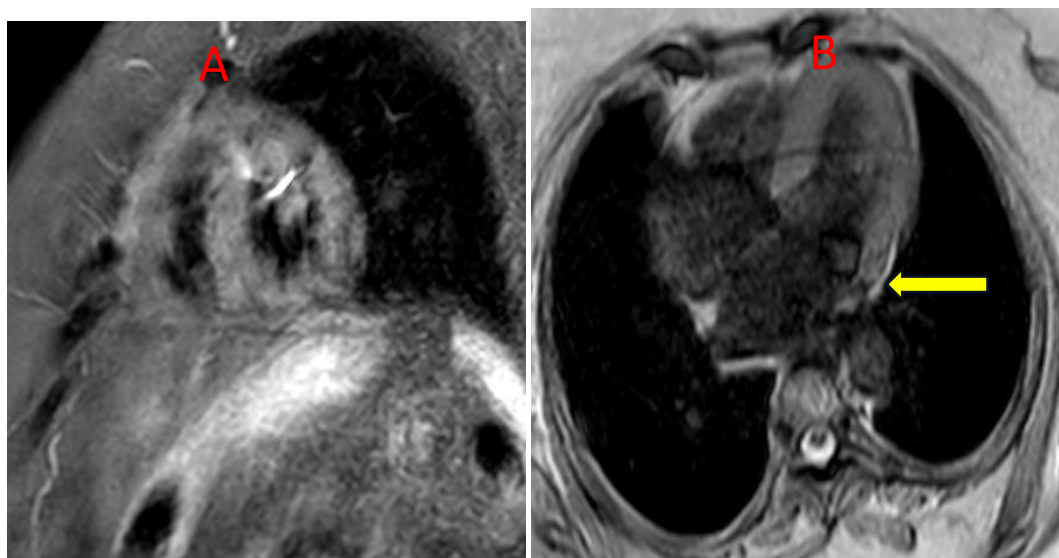


Fig. 2. Cardiac MRI: A- Sagittal cross section view flip angle 90°: showing a small sessile mass attached to the ventricular side of the posterior mitral valve leaflet, measuring 20x15 mm with a broad base, B- Transverse cross section view T1 flip angle 25°: displaying low T2 signal intensity and isointensity on T1 of the mass evoking cardiac fibroelastoma (yellow arrow)

triglycerides 1.38 g/L), HbA1C at 8.8%, impaired renal function with a creatinine level of 11.8 mg/L and urea level of 0.40 g/L (estimated GFR using the MDRD formula was 49 mL/min/1.73m²). The rest of the hydro electrolytic assessment was unremarkable.

The patient presents lesions suggestive of Nevus on the face and trunk, and a large "café-au-lait" spot under the left breast. An ophthalmological examination was requested in this context,

revealing nummular neurofibromas in the right eye associated with papillary pallor. This was further complemented by a cerebral CT scan which detected signs of vascular leukoencephalopathy.

A positron emission tomography (PET SCAN) was requested to look for a metastatic extension of the rectal cancer which revealed a hypermetabolic circumferential rectal thickening in favor of a progressive residual disease,

hypermetabolism at the level of the left ventricle cavity attached to the mass found on the transthoracic echocardiography (Fig. 3), hypermetabolic bilateral upper paratracheal lymphadenopathy and hypermetabolic left midlobar thyroid nodules.

Faced with this inconclusive aspect, a mass resection surgery was carried out (mass excision and conservative treatment of the mitral valve), the histopathology study of the surgical specimen concluded that it was a cardiac papillary fibroelastoma (Fig. 4).

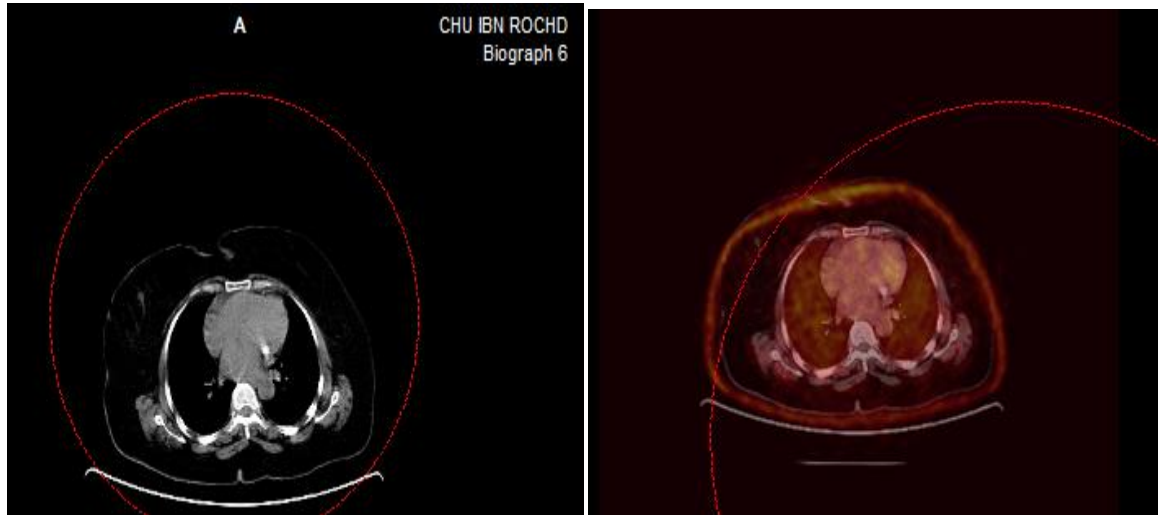


Fig. 3. PET scan A-B fusion images: hypermetabolism at the level of the left ventricle cavity attached to the mass

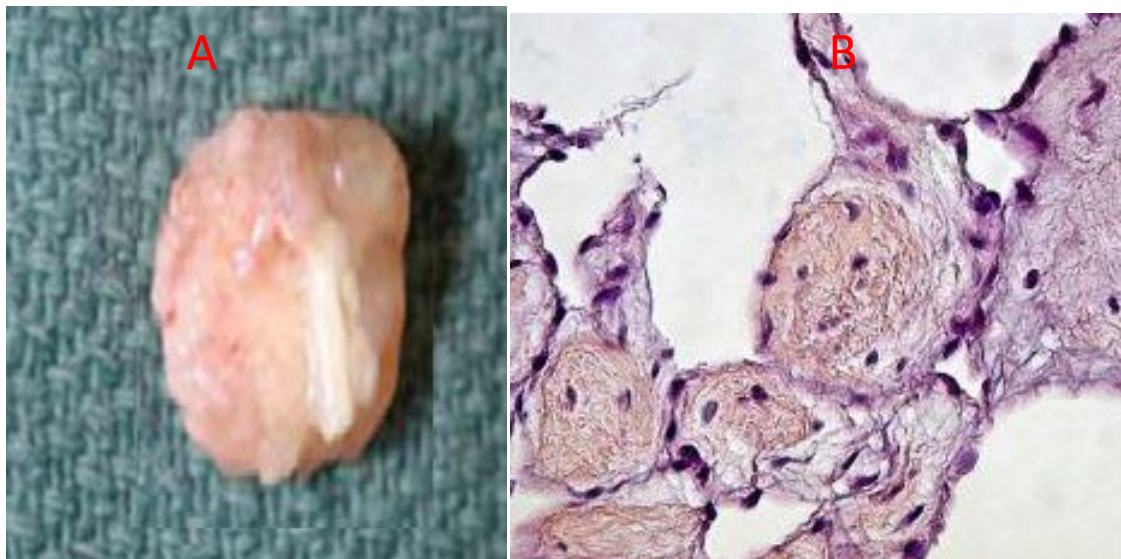


Fig. 4. A- surgical specimen: soft oval shape mass measuring 22mm in length, B-histology of the specimen showing papillary hyalinized hypocellular stroma with endocardial lining associated with small fibrin confirming the diagnosis of cardiac papillary fibroelastoma

3. DISCUSSION

With an incidence of up to 0.33% in one autopsy series, CPF is the third most common primary cardiac tumor, after myxoma and lipoma [5]. Although most CPF patients are asymptomatic,

CPF is often associated with severe complications. The correct diagnosis is therefore important. The most common clinical presentations include stroke, acute coronary syndrome, heart failure, syncope, mesenteric ischemia, pulmonary embolism, and sudden

death due to embolization, either from thrombus or from the tumor itself [6]. In our case, patient was asymptomatic and the diagnostic was fortuitous during assessment prior for chemotherapy.

Over 80% of CPFs are found on the valvular endocardium [7]. In particular, the aortic valve is the most common site. CPFs can also exist on the mitral, tricuspid, or pulmonary valves, right atrial endocardium, and endocardial surfaces in both ventricles, including the papillary muscles and interventricular septum. It occurs less frequently on the mitral chordae [7,8]. The average size of a CPF is approximately 1 cm in diameter, but their size can range from 0.2- 4.6 cm. Forty-four percent of CPFs have a 1-3 mm stem; this mobile type of CPF appears to be more likely to embolize [4,7,9]. However, in our patient; the mass was unusually located on the posterior mitral valve leaflet occupying almost all of its length extending to the endocardium of the ventricle wall without neither obstruction nor regurgitation of the mitral valve.

In adults, CPF are described as solitary, round or oval, or irregular-shaped tumours, generally small, with a mean size of 10 mm, half of them have stalks and are often mobile [10,11]. Imaging modalities for the diagnosis include TTE, transoesophageal echocardiography (TEE), cardiac MRI, and computed tomography (CT scan) [12]. TTE has excellent diagnostic sensitivity and specificity (88.8% and 88.7%, respectively). However, when a smaller CPF (<0.2 cm) is suspected, TEE has greater sensitivity (76.6%) than TTE (61.9%) (4). In some particular cases, magnetic MRI is useful to assist in the diagnosis of CPF. MRI allows a high soft-tissue characterization, multi-planar imaging, and high temporal resolution [7]. As in our case, transthoracic echocardiography was performed first and then cardiac MRI for better tissue characterization. We also conducted a PET scan to eliminate a secondary localization of rectal adenocarcinoma extension. At this level, the diagnosis of cardiac papillary fibroelastoma could not be confirmed, then we opted for surgical mass excision and histology exams after heart team discussion.

There are no specific guidelines for treatment of CPF. Surgical excision is the recommended treatment unless there are contraindications [13]. The indication for operation is determined by the patient's overall characteristics and comorbidities/risk factors, presence or absence

of symptoms, the type of tumor, size, location, and operative and long-term outcomes [14]. In our case, since the PET can could not differentiate the nature of the mass, after a heart team discussion, surgery was indicated and histology study of the mass confirmed a cardiac papillary fibroelastoma. The lecture in this case is that not all cardiac masses are secondary localisation in patient diagnose with cancer. Histological studies to confirm mass nature is crucial if multimodality imaging approaches are doubtful as it changes the status of cancer patient of which the primitive site is extra-cardiac, as well as changes in their therapy protocol.

4. CONCLUSION

It should be stressed that echocardiography is not 100% accurate in making a tissue diagnosis of intracardiac masses, highlighting the role of a multimodality imaging approach.

Cardiac mass can have different localisation, thorough workout is needed in patient with diagnosed extra-cardiac cancer and intracardiac masses in other to differentiate benign tumor from cancer metastasis. The crucial involvement of both cardiology and oncology teams in therapy decision helps in changing patient's prognosis.

CONSENT

As per international standards or university standards, patient(s) written consent has been collected and preserved by the author(s).

ETHICAL APPROVAL

As per international standards or university standards written ethical approval has been collected and preserved by the author(s).

COMPETING INTERESTS

Authors have declared that no competing interests exist.

REFERENCES

1. George Samanidis, Charalampos Katselis, Constantinos Contrafouris, Theofani Antoniou, konstantinos Perreas. Unusual location of a cardiac papillary fibroelastoma. *Cardiol res.* 2017;8:336-338.
2. Dominika M Zoltowska, Edin Sadic, Kyeesha Becoats, Shreya Ghetiya, Aleem Azal Ali, Srinivasan Sattiraju, Emil Missov.

- Cardiac papillary fibroelastoma. *J Geriatr Cardiol* 2021; 18: 346–351.
3. Itta Kawamura, Misayo Hayashi, Hiromitsu Kanamori, Masanori Kawasaki, Kazuhiko Nishigaki, Shinya Minatoguchi, Yusuke Mizuno and Hirofumi Takemura. Cardiac Papillary Fibroelastoma Originating from the Mitral Valve Chordae. *Intern Med* 2015; 54:3161-3164.
 4. Sun JP, Asher CR, Yang XS et al. Clinical and echocardiographic characteristics of papillary fibroelastomas: A retrospective and prospective study in 162 patients. *Circulation*. 2001;103:2687-2693.
 5. Teruyoshi Uetani, Shinji Inaba, Yuki Yamanishi, Riko Kitazawa, and Osamu Yamaguchi. Cardiac papillary fibroelastoma: An unusual cause of hemichorea secondary to tumour Embolism. *European Heart Journal - Case Reports*. 2022;6;1–2.
 6. Gowda RM, Khan IA, Nair CK et al. Cardiac papillary fibroelastoma: A comprehensive analysis of 725 cases. *Am Heart J*. 2003;404-410;146.
 7. Palaskas N, Thompson K, Gladish G, Agha AM, Hassan S, Iliescu C, Kim P, Durand JB, Lopez-Mattei JC. Évaluation et prise en charge des tumeurs cardiaques. Options de traitement *Curr Cardiovasc Med*. 2018;20:29.
 8. Nawaz MZ, Lander AR, Schussler JM et al. Tumor excision versus valve replacement for papillary fibroelastoma involving the mitral valve. *Am J Cardiol*. 2006;97:759-764.
 9. Carlos J. Collado-Rivera, Krisela Vojniku, Mohit Sharma, Harold A. Fernandez, Alan T. Kaell. Cardiac Papillary Fibroelastoma: Atypical Presentation Mimicking Infective Endocarditis With False Positive Commensal Blood Cultures. *Cureus*. 2023; 15:e42660.
 10. Sarah Dénes, Benoît Daron, Marie Behaeghe, Marie-Christine Seghaye. Cardiac papillary fibroelastoma of a bicuspid aortic valve in an adolescent: A case report *Clinics and Practice* 2019; 9:1135.
 11. Shi L, Wu L, Fang H, et al. Identification and clinical course of 166 pediatric cardiac tumours. *Eur J Pediatr*. 2017;176:253-60.
 12. Müller S, Feuchtner G, Bonatti J et al. Value of transesophageal 3D echocardiography as an adjunct to conventional 2D imaging in preoperative evaluation of cardiac masses. *Echocardiography*. 2008;25:624-31.
 13. Mazur P, Kurmann R, Klarich KW et al. Operative management of cardiac papillary fibroelastomas. *J Thorac Cardiovasc Surg*; 2022
 14. Joana Duarte Rodrigues, João Ferreira, Jorge Almeida, Manuel Campelo, Maria Júlia Maciel, Paulo Pinho. Cardiac papillary fibroelastoma: Report of a surgical series. *Rev Port Cardiol*. 2018;37: 981-986.

© 2023 Njie et al.; This is an Open Access article distributed under the terms of the Creative Commons Attribution License (<http://creativecommons.org/licenses/by/4.0>), which permits unrestricted use, distribution, and reproduction in any medium, provided the original work is properly cited.

Peer-review history:

The peer review history for this paper can be accessed here:

<https://www.sdiarticle5.com/review-history/108690>