



Feline Mesenteric form of Multinodal Lymphoma: A Case Report

M. Chandrasekar¹, S. Venkatesan^{2*}, N. Sai Aravindh¹, A. P. Nambi¹,
P. S. Thirunavukkarasu¹ and S. R. Srinivasan¹

¹Department of Veterinary Clinical Medicine, Madras Veterinary College, Chennai, India.

²Department of Veterinary Anatomy, Madras Veterinary College, Chennai, India.

Authors' contributions

This work was carried out in collaboration between all authors. Authors MC and NSA identified the patient and went in for assessment and complete therapy. Authors SV and APN analyzed the data collected and provided valuable statistical data regarding occurrence pattern in felines and major management strategies and managed the literature searches and critically reviewed the manuscript.

Authors PST and SRS aided in patient intensive care and management along with training in management strategies for the complete recovery of the patient. All authors read and approved the final manuscript.

Article Information

DOI: 10.9734/ARRB/2016/22436

Editor(s):

(1) George Perry, Dean and Professor of Biology, University of Texas at San Antonio, USA.

Reviewers:

- (1) Nelida Virginia Gómez, Buenos Aires University, Argentina.
 - (2) Belisario Dominguez Mancera, University of Veracruz, Veracruz, Mexico.
 - (3) Juan Carlos Troiano, University of Buenos Aires, Argentina.
 - (4) Golam Hafiz, Bangabandhu Sheikh Mujib Medical University, Dhaka, Bangladesh.
- Complete Peer review History: <http://sciencedomain.org/review-history/12550>

Case Study

Received 1st October 2015
Accepted 23rd November 2015
Published 3rd December 2015

ABSTRACT

Introduction: Feline lymphoma is one of the most important forms of tumor which is not completely understood. Complications and pathogenesis of tumor growth and development is quite difficult to diagnose due to varied etiology and pathogenesis. Mesenteric form of lymphoma is quite rare (8-18%) in felines and tumor regression and palliation are quite challenging in these patients.

Case Presentation: An 8 year old, desi, short-hair breed feline was reported to the hospital with the consistent respiratory distress and abnormally swollen neck for the past two weeks. The feline was a recently adopted stray pet and the preventive strategies like vaccination, birth control etc., were not undertaken as per the history collected. The animal was diagnosed as stage IV high

*Corresponding author: E-mail: dvenkat1971@gmail.com;

grade, anaplastic large cell lymphoma after employing various diagnostic strategies. The animal was treated with University of Wisconsin-Madison Modified Chemotherapy Protocol which led to the successive regression of the condition.

Conclusion: Lymphoma is one of the common hematological malignancies of felines whose management still remains challenging. There are various forms of lymphoma depending on the site of occurrence and metastasis. Chemotherapy and surgical options are the best available strategies in management of lymphoma. Multi-nodal lymphoma is occur in 10-20% of the felines. Chemotherapy protocol as standardized by the University of Wisconsin-Madison is still efficient in management of lymphoma in felines irrespective of the stage and clinical grade of presentation.

Keywords: Feline; lymphoma; mesenteric form; chemotherapy.

1. INTRODUCTION

Hematopoietic tumors like lymphoma (LA), acute myeloid leukemia (AML) are quite common in felines [1]. The occurrence has been reported relatively higher in non-vaccinated and poorly vaccinated animals [1,2]. Though vaccination plays an important role in the prevention of the occurrence, the exact reasons for reduced occurrence is still under study. One possible reason could be due to the vaccination against Feline Leukemia virus (FeLV).

In general, it is considered that cats are at a greater risk for a broad range of anatomical and histological forms of lymphoma than any other species. There are various forms of lymphoma that may occur in felines. These include nasal LA, cranial mediastinal LA, multicentric LA, renal LA, central nervous system (CNS) LA, and alimentary LA and also malignant forms in various lymphatic drainage regions. In comparison with canine lymphoma, feline lymphoma is more acute and much more complicated and, response to therapy is also exaggerated in felines than in canines.

The alimentary form of lymphoma is more common in felines than in human beings and canines [2]. An increased occurrence of the alimentary form of lymphoma is reported to up to 72% in all vaccinated felines [3]. This could be due to various other etiology like environmental tobacco smoke [4], helicobacter infection [5], etc. The multi-nodal/ multicentric form of lymphoma with lymph node involvement along with metastasis to liver or the spleen is quite rare (10-20%) in felines [2]. The major lymph nodes involved include the mediastinal, mesenteric, iliac, inguinal, submandibular lymph nodes.

The commonly employed diagnostic strategies include PCR for identification of FIV antigen to rule out viral causes for malignancy and enzyme

linked Immuno-Sorbent assay [6,7]. Under a clinical setup, ultrasonography guided biopsy of the enlarged lymph nodes can be obtained for assessment of the tumor. The flow cytometry is considered to be the best diagnostic strategy [8] for a clinical diagnosis of lymphoma which can be employed if necessary. Bone marrow biopsy is very essential to stage the form of tumor and as well as to assess invasion into the marrow [9,10]. Based on cells involved and anaplastic changes, lymphoma can be classified based on various systems like the Kiel system, Rappaport system, Luke & Collins System, Working formulation system [7].

2. PRESENTATION OF CASE

An 8 year old of the desi short-hair breed Tomcat was admitted to the Critical Care Unit, Madras Veterinary College, Chennai, with the history of respiratory distress and never been vaccinated before. Further history suggested that respiratory distress occurred in a slowly progressing phase. The initial clinical assessment suggested that masses in the submandibular region (Fig. 1) and pleural effusion. The patient was carefully placed on sternal recumbence and the effusate fluid in the pleural space was gradually aspirated out and sent in for laboratory assessment. Subsequently, under local anesthesia, Fine Needle Aspiration Biopsy (FNAB) of the swollen mass in the submandibular region was carried out. For further assessment of the patient, abdominal ultrasonography and radiography of the thorax was done. The ultrasonographic assessment revealed that mesenteric lymph nodes (Fig. 2) were enlarged and were compressing the intestinal walls. Under general anesthesia, the patient was carefully positioned and ultrasound guided biopsy of the enlarged mesenteric lymph node was obtained. The radiography revealed mediastinal lymph node enlargement. For further staging, as per standard operating procedure,

core biopsy of the bone marrow was obtained. The hematology and serum biochemical panel analysis was also carried out.

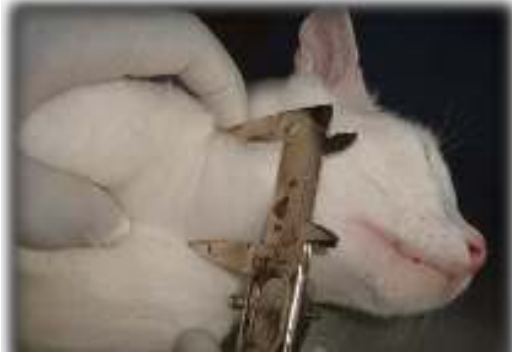

Fig. 1. Enlarged submandibular lymph nodes of the patient

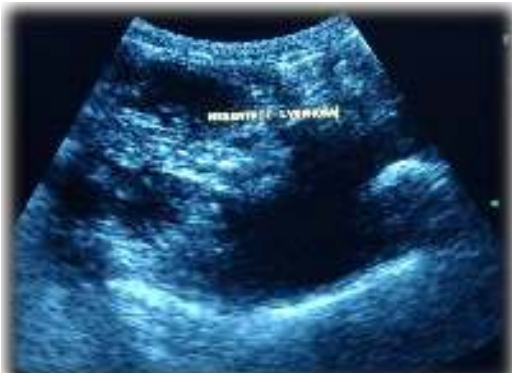

Fig. 2. Ultrasonographic assessment revealing mesenteric lymph node involvement

3. LABORATORY EXAMINATION AND INTERPRETATION

The hematological examination revealed that the animal was anemic with marked leukopenia. Serological examination revealed characteristic

paraneoplastic syndrome associated with T-cell lymphoma and hypercalcemia. The effusate fluid from pleural space smeared on clean glass slides and stained by the May-Grunwald-Giemsa staining technique. It revealed reactive lymphocytes. The FNAB of the submandibular masses revealed multinuclear giant cells with anaplastic changes. The lympho-granuloma bodies (LGB) were also associated with the giant cells (Fig. 3). Similarly, biopsy from the mesenteric lymph node also revealed large, multinucleated giant cells with major anaplastic changes and diminished cellular inhibition suggestive of 'Anaplastic Large Cell Lymphoma' (Fig. 3). Based on NCI-Working Formulation System of Classification, this patient was characterized to be ailing from High-grade Lymphoma.

4. GRADING AND STAGING

Based on presence of metastatic lesions in the liver and the involvement of mediastinal lymph nodes and without any form of bone marrow infiltration, the condition was diagnosed as Stage IV High grade, Anaplastic large Cell Lymphoma as per the WHO system of classification.

5. THERAPEUTIC REGIME

The furosemide therapy at the rate of 3mg/kg body weight for the first four days was done to relieve pleural effusion. The chemotherapy protocol as prescribed by University of Wisconsin-Madison for feline lymphoma (Table 1) was subsequently initiated. The protocol was followed for the next 25 weeks at the prescribed periods. The hematological assessment regarding neutrophil levels were assessed before every therapeutic procedure (Fig. 4). The patient was maintained under critical care for a minimum of 3 hours following

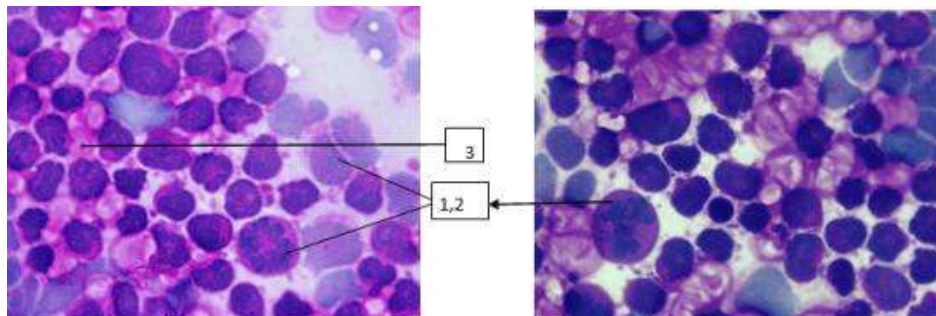


Fig. 3. May-Grunewald-Giemsa staining of the mesenteric lymph node biopsy showing: 1. Poor cellular Differentiation 2. Large cells undergoing anaplastic and mitotic changes.3. LG Bodies

chemotherapy on all prescribed days. The size of the submandibular mass (Fig. 1) was measured as 8 cm long and 2.7 cm wide on the day of first clinical presentation. The assessment of lymph nodes was carried out regularly on every visit to the hospital. A gradual reduction in the size of the lymph nodes was observed from the third dose of the chemotherapy. The final assessment

was carried out in the 23rd week and the lymph nodes have completely returned to the normal size and measured as 0.6 cm long and 0.25 cm wide.

The therapeutic regimen followed for the management of Anaplastic Large cell Lymphoma in this patient is as follows:

Table 1. University of Wisconsin-Madison modified chemotherapy protocol

S. no	Week	Drug administered	Dosage
1.	1	VINCRISTINE L-ASPARAGINASE PREDNISOLONE	0.5-07 mg/m ² IV 400U/kg SC 2 mg/kg PO
2.	2	PREDNISOLONE CYCLOPHOSPHAMIDE	2 mg/kg PO 200 mg/m ² IV
3.	3	VINCRISTINE PREDNISOLONE	0.5-07 mg/m ² IV 1 mg/kg PO
4.	4	DOXORUBICIN PREDNISOLONE	25 mg/m ² IV 1 mg/kg PO
5.	6	VINCRISTINE	0.5-07 mg/m ² IV
6.	7	CYCLOPHOSPHAMIDE	200 mg/m ² IV
7.	8	VINCRISTINE	0.5-07 mg/m ² IV
8.	9	DOXORUBICIN	25 mg/m ² IV
9.	11	VINCRISTINE	0.5-07 mg/m ² IV
10.	13	CYCLOPHOSPHAMIDE	200 mg/m ² IV
11.	15	VINCRISTINE	0.5-07 mg/m ² IV
12.	17	DOXORUBICIN	25 mg/m ² IV
13.	19	VINCRISTINE	0.5-07 mg/m ² IV
14.	21	CYCLOPHOSPHAMIDE	200 mg/m ² IV
15.	23	VINCRISTINE	0.5-07 mg/m ² IV
16.	25	DOXORUBICIN	25 mg/m ² IV

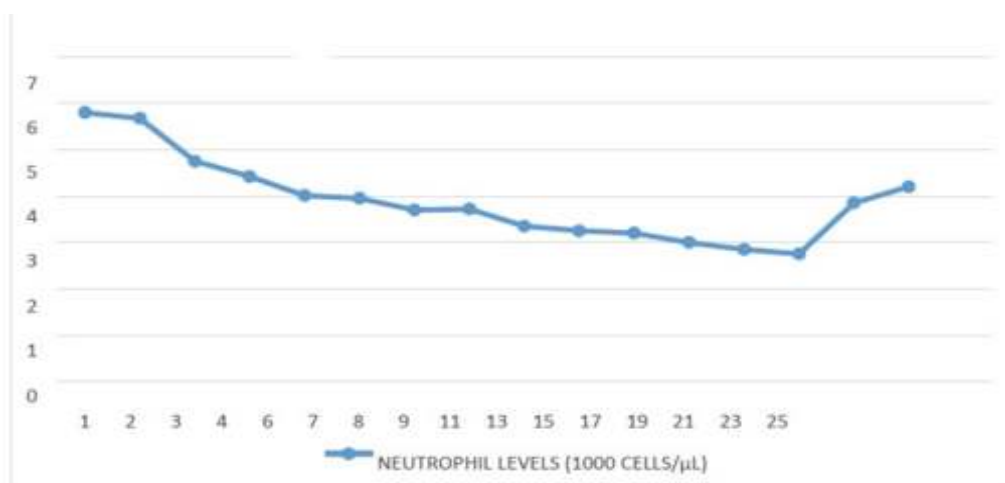


Fig. 4. Neutrophil levels (1000 cells/μl) during the therapeutic regimen

6. DISCUSSION

Lymphoma of felines is quite a common condition as it is a Feline Leukemia Virus (FeLV) induced lympho-proliferative disease. The condition is more common in unvaccinated pets rather than vaccinated pets. The prevalence of FeLV virus among feral and stray felines making it easily accessible to unvaccinated and poorly vaccinated pets. It is also suggested that 25% of felines with lymphoma do have FeLV Antigenemia [2]. The other etiologies for lymphoma include Helicobacter infection, diet and environmental tobacco smoke [4,5]. The occurrence of the disease is gradually reducing due to various control strategies like reduced exposure to stray and feral felines, vaccination etc. The alimentary lymphoma affects predominantly middle- to old-aged domestic crossbred cats (median age 10–13 years) [10].

The B cell lympho-types are commonly found in the mesenteric form but T cell Lymphoma do have mesenteric involvement when the tumor has progressed to multicentric phase [11]. The multicentric lymphoma usually results in reactive or hyperplastic lymph nodes. During this phase, there will be marked enlargement of nearly all lymph nodes in the body. The most common clinical feature during this phase is subsequent involvement of mediastinal lymph nodes leading to accumulation of effusate fluid in the pleural space [9]. This feature compromises respiration. The Fine Needle aspirate of the lymph node must be done compulsorily to rule out Hodgkin's Lymphoma. If possible, this can be confirmed by Flow-cytometric analysis [12,13] or immunohistochemistry (IHC) or an immunocytochemistry can be done for confirmation. Flowcytometry for assessment of Human CD79 acy can be done to identify between T cell and Human CD 3cy can be employed for B cell Lymphoma.

Radiation therapy and lymph node resection are the best therapeutic protocol against Multicentric Lymphoma. But due to cost constraints and various paraneoplastic syndromes, surgical options and radiation therapy were ruled out in this patient. The patient was switched onto chemotherapeutic strategy which did provide better results.

7. CONCLUSION

Multicentric form of lymphoma is a very rare form of lymphoma occurring in 10-20% of patients affected. Of this scale, one third of patients do

have FeLV Antigenemia [2]. This form has multiple lymph node involvement, initially the subcutaneous lymph nodes followed by Liver and Splenic metastasis. Also a few patients are presented with subsequent Mesenteric form of Lymphoma. The Fine Needle Aspiration Biopsy of Mesenteric Lymph nodes and the Subcutaneous Lymph nodes followed by various imaging techniques like radiographic lymphangiography, ultrasonography assessment are the various procedures helpful in diagnosis. Flow cytometric assessment of blood and lymph node aspirate can be done for confirmation. The best therapeutic regimen is surgical excision of the lymph nodes if possible, radiation therapy and chemotherapy but chemotherapy is the only feasible protocol available. The University of Wisconsin-Madison modified chemotherapy strategy for lymphoma is the best protocol available as mentioned above. Chemotherapy strategy along with patient care in palliation and paraneoplastic syndrome management were essential for a successful recovery.

CONSENT

It is not applicable.

ETHICAL APPROVAL

It is not applicable.

ACKNOWLEDGEMENTS

The authors thank Dr. S. Vairamuthu, and Dr. S. Subhapiya, Centralized Clinical Laboratory, Madras Veterinary College for their major assistance in histopathology.

COMPETING INTERESTS

Authors have declared that no competing interests exist.

REFERENCES

1. Vail DM, Moore AS, Ogilvie GK. Feline lymphoma (145) cases: Proliferation indices, CD3 immunoreactivity and their association with prognosis in 90 cats. *J. Vet. Internal Med.* 1998;12:349-354.
2. Louwerens M, London CA, Pederson NC. Feline lymphoma in the post-feline leukemia virus era. *J. Vet. Internal Med.* 2005;19:329-335.
3. Richter KP. Feline gastrointestinal lymphoma. *Veterinary Clinics of North*

- America. *Small Anim. Pract.* 2003;33(5): 1083-1098.
4. Bertone ER, Snyder LA, Moore AS: Environmental Tobacco smoke and risk of malignant Lymphoma in pet cats. *American J. Epidemiol.* 2002;156:268-273.
5. Bridgeford EC, Marini RP, Feng Y. Gastric Helicobacter species as a cause of feline gastric lymphoma: A Viable Hypothesis. *Veterinary Immunol. Immunopathol.* 2008; 123:106-113.
6. Wilson MH. Feline alimentary lymphoma-demystifying the Enigma. *Top companion Med.* 2008;23(4):177-184.
7. Ersboll J, Schultz HB, Thomsen BL, Keiding N, Nissen NI. Meningeal involvement in non-Hodgkin's lymphoma: symptoms, incidence, risk factors and treatment. *Scandinavian J. Hematol.* 1985; 35:487-496.
8. Culmsee S, Mischke N. Possibilities of flow cytometric analysis for immunophenotypic characterization of canine lymphoma. *J. Vet. Med. Association.* 2001;47:199-206.
9. Hittmair K, Krebitz-Gressl E, Kubber-Heiss A. Feline alimentary lymphosarcoma: radiographic, ultrasonographic, histologic, and viral findings. *Wien Tierarztliche Monatsschrift.* 2000;87(6):174-183.
10. Valli VE, Jacobs RM, Norris A. The histologic classification of 602 cases of feline lympho- proliferative disease using the National Cancer Institute Working formulation. *J. Vet. Diagnostic Invest.* 2000;12(4):295-306.
11. Court EA, Watson ADJ, Peaston AE. Retrospective study of 60 cases of feline lymphosarcoma. *Australian Vet. Journal.* 1997;75(6):424-427.
12. Moore PF, Rositto PV. Development of monoclonal antibodies to canine T- cell-receptor complex (TCR/CD3) and their utilization in the diagnosis of T cell neoplasia. *J. Vet. Pathol.* 1993;30:457.
13. Barrs V, Beatty J. Feline alimentary lymphoma 1. Classification, risk factors, clinical signs and non-invasive diagnostics. *Journal of Feline Medicine and Surgery.* 2012;14(3):182-190.

© 2016 Chandrasekar et al.; This is an Open Access article distributed under the terms of the Creative Commons Attribution License (<http://creativecommons.org/licenses/by/4.0>), which permits unrestricted use, distribution, and reproduction in any medium, provided the original work is properly cited.

Peer-review history:
The peer review history for this paper can be accessed here:
<http://sciedomain.org/review-history/12550>