

Balloon Mitral Valvotomy in Gestational Women with Symptomatic Mitral Stenosis

**Prem Krishna Anandan¹, Arun Kaushik^{1*}, K. Tamilarasu¹, G. Rajendran¹,
Shanmuga Sundaram¹, P. Ramasamy¹ and R. B. Vidyakar¹**

¹Department of Cardiology, PSG Hospitals, Peelamedu, Coimbatore, India.

Authors' contributions

This work was carried out in collaboration among all authors. Author PKA designed the study, performed the statistical analysis, wrote the protocol and wrote the first draft of the manuscript. Authors AK, KT, GR, SS and PR managed the analyses of the study. Author RBV managed the literature searches. All authors read and approved the final manuscript.

Article Information

DOI: 10.9734/CA/2020/V9i330134

Editor(s):

- (1) Professor Stefano Omboni, Italian Institute of Telemedicine, Italy.
- (2) Dr. Gen-Min Lin, Hualien-Armed Forces General Hospital, National Defense Medical Center, Taiwan.
- (3) Professor Francesco Pelliccia, University La Sapienza, Italy.
- (4) Dr. Thiago Andrade de Macêdo, Cardiology Division Heart Institute (InCor), Brazil.

Reviewers:

- (1) Udaya Prashant Ponangi, The Townsville Hospital, Australia.
 - (2) Md. Mashiul Alam, Jahurul Islam Medical College and Hospital, Bangladesh.
 - (3) Awofadeju Stephen Olajide, Obafemi Awolowo University Teaching Hospitals, Nigeria.
- Complete Peer review History: <http://www.sdiarticle4.com/review-history/53614>

Original Research Article

Received 26 December 2019
Accepted 01 March 2020
Published 12 March 2020

ABSTRACT

Background: Rheumatic valvular heart disease, commonly mitral stenosis, complicate 1% of pregnancies. Balloon mitral valvuloplasty (BMV) is an established treatment of rheumatic mitral stenosis. Aim of the study was to assess the safety and efficacy of Balloon mitral valvuloplasty in pregnant women with severe mitral stenosis.

Materials and Methods: 66 patients who failed to respond to medical therapy undergoing BMV during pregnancy were analysed in this retrospective study. Mitral valve area (MVA), transmitral Mean valve gradient (MVG), and mitral regurgitation (MR), Pulmonary artery pressure (PAP) were assessed before and 24 hours after the procedure by transthoracic echocardiography. Patients were followed up to one month post BMV and neonates were monitored for the adverse effect of radiation.

*Corresponding author: E-mail: drarunkaushik@gmail.com;

Results: Mitral valve area increased from $0.83 \pm 0.13 \text{ cm}^2$ to $1.38 \pm 0.29 \text{ cm}^2$ ($P = 0.007$). Mean gradient mitral valve gradient decreased from $15.5 \pm 7.4 \text{ mmHg}$ to $3.36 \pm 2.36 \text{ mmHg}$ ($P = 0.001$). Pulmonary artery pressure decreased from 65.24 ± 17.9 to 50.45 ± 15.33 ($P = 0.012$). No maternal death, intrauterine growth restriction was observed.

Conclusion: Balloon mitral valvuloplasty has favourable immediate good outcomes for mothers and newborns.

Keywords: Balloon mitral valvuloplasty; mitral stenosis; pregnancy.

1. INTRODUCTION

Valvular heart diseases complicate 0.5 to 1.5 percent of all pregnancies [1]. Mitral stenosis is the most common form with increased pregnancy and delivery complications for both mother and neonate [2]. During pregnancy physiological hemodynamic changes of the circulation are the main cause of mitral stenosis decompensation [3]. The symptoms are poorly tolerated especially beyond the second trimester and in other cases may lead to frank heart failure [4,5]. Most pregnant women with mitral stenosis can be adequately treated with medical therapy and sometimes an invasive procedure is mandatory [6–9]. Before the introduction of percutaneous transluminal mitral commissurotomy (PTMC) surgical commissurotomy was the sole answer to pregnant women with refractory symptoms. The high mortality rate (1.8% to 33%) of surgery and favourable outcome of PTMC in relieving symptoms plus a lower risk of fetal death made PTMC more popular [10–15]. Prospective studies on PTMC and its effect on pregnancy outcome and neonate are needed. In this study, we aimed to investigate the clinical outcome of pregnant women undergoing PTMC and to assess the neonate condition after one month [16].

2. MATERIALS AND METHODS

A series of 66 pregnant women undergoing PTMC in Department of Cardiology, PSG Hospitals, Peelamedu, Coimbatore from September 2015 to October 2019 were analysed in this descriptive study. The study was approved by ethical committee.

2.1 Inclusion Criteria

1. Patients with severe mitral stenosis.
2. Progressive symptoms during any trimester in spite of adequate medical therapy.
3. History of acute pulmonary edema during pregnancy.

4. LAA clot confined to body of appendage (Type Ia-Manjunath et al.).

2.2 Exclusion Criteria

- 1) Severe mitral regurgitation.
- 2) Left atrial thrombus.

PTMC was performed using Accura balloon. Balloon diameters were chosen according to the patient's height using Hung's formula. Lead shields were used to protect the abdomen during the procedure limiting fetal radiation exposure. Fluoroscopy time was measured during the procedure. Heparin (80 IU/kg, intravenously) was administered twice during the procedure. Mitral valve area, transmitral valve gradient and severity of mitral regurgitation, PA pressures were measured before and 24 hours after the procedure and during long-term follow-up using two-dimensional echocardiography to evaluate the efficacy of the procedure. Transthoracic echocardiography was performed with a Philips HD7 machine with a 2.5 MHz probe, and images obtained in parasternal long and short axis and apical two- and four-chamber views. Mitral valve morphology was also evaluated before the procedure using criteria by Wilkins et al. [17] Mitral valve velocities were assessed with continuous-wave Doppler and mitral valve area was estimated from the planimetry method [18]. Mitral regurgitation was graded as mild, moderate, or severe according to jet length and area. Clinical follow-up after hospital discharge was accomplished by medical visits 1, 3, 6 months after discharge. Finally patients were scheduled to be visited every 6 months for lifetime and to report earlier if symptomatic [16].

All patients were advised injectable benzathine penicillin 12 lac units deep intramuscular once in 21 days. Moreover, all babies were examined after delivery for any malformation and their development was assessed after one month over telephone. Continuous variables are expressed in mean \pm SD. Comparison between the groups

was accomplished by Student's two-tailed test. A P value of 0.05 was considered of statistical significance.

3. RESULTS

Demographic data are summarized in Table 1. Mean maternal age was 27 ± 5.4 years and mean gestational age was 22.8 ± 6.4 weeks. PTMC was performed successfully in all patients. After the procedure, mean MVA increased from $0.83 \pm 0.13 \text{ cm}^2$ to $1.38 \pm 0.29 \text{ cm}^2$ (P-value 0.007). Mean MVG significantly decreased from $15.5 \pm 7.4 \text{ mmHg}$ to $3.36 \pm 2.36 \text{ mmHg}$ (P-value 0.001). Also, a significant decrease in pulmonary artery pressure was detected from $65 \pm 18 \text{ mmHg}$ to $50 \pm 15 \text{ mmHg}$ (P = 0.012). Mean left atrial pressure decreased significantly from 28.3 ± 7.2 to 15 ± 5.45 . No significant change occurred in left ventricular ejection fraction and

left ventricular end diastolic volume before and after procedure (Table 2). Symptoms of heart failure improved in all patients, and none of them experienced NYHA class III or IV (Table 3). Mitral regurgitation in 12 patients changed from mild to moderate and in one case to severe after procedure and this patient was 2 weeks short of due and hence underwent simultaneous mitral valve replacement and lower abdomen cesarean section without any complications (Table 4). 3 patients developed cardiac tamponade during septal puncture, but all 3 underwent pericardiocentesis with successful completion of PTMC. No maternal death, abortion, or intrauterine growth retardation was reported. Total fluoroscopy time was 8 mins (average). Infants assessed after one month by paediatrician and all had normal growth and development which was verified over telephone [16].

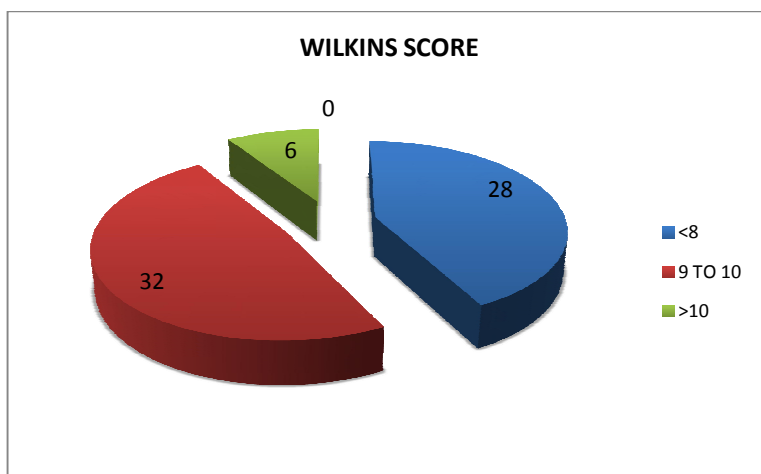


Fig. 1. Wilkins score of study population

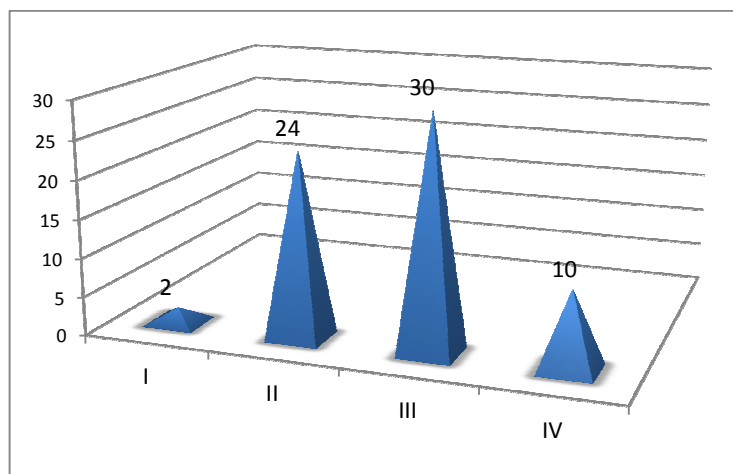


Fig. 2. NYHA class pre PTMC

Table 1. Baseline characteristics of study population

Mean Maternal Weight(kg)	Mean Maternal height(cm)	Mean age(year)	Mean gestational age(weeks)	NYHA (1)	NYHA (11)	NYHA (111)	NYHA (IV)
48.5	150.4	27 ± 5.4	22.8 ± 6.4	2	24	30	10

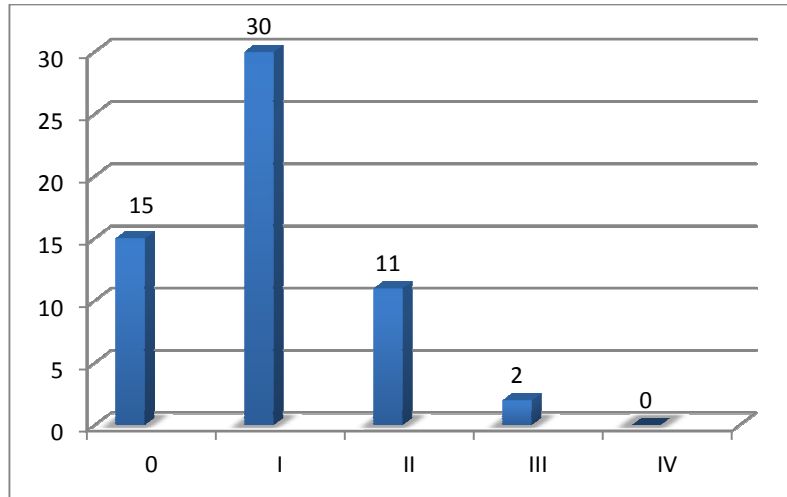


Fig. 3. Nyha class post procedure

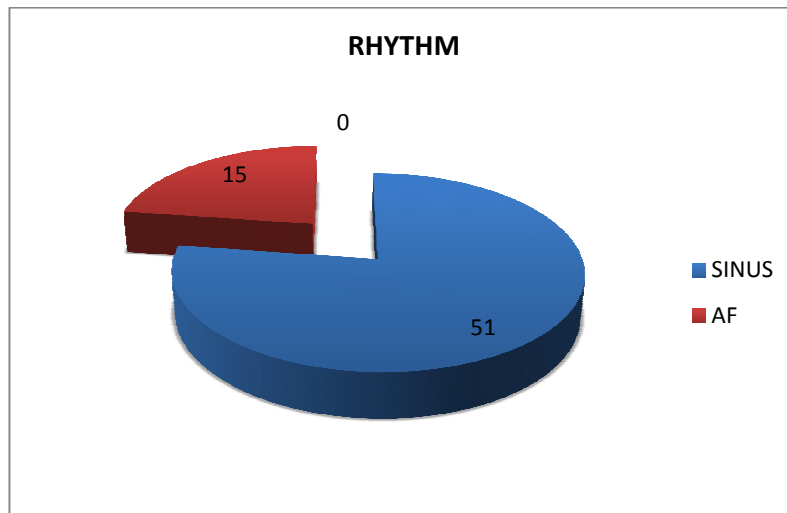


Fig. 4. Rhythm status

Table 2. Echocardiographic parameters

Wilkins score			No Mitral regurgitation	Mild Mitral regurgitation	Moderate Mitral regurgitation	Thrombus confined to left atrial appendage
<8	9-10	>10				
28	32	6	24	36	6	2

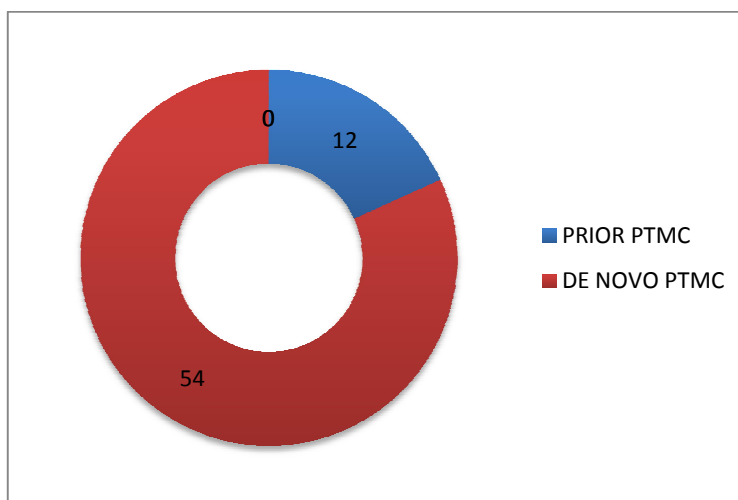


Fig. 5. Prior PTMC

Table 3. Electrocardiogram

Sinus rhythm	Atrial fibrillation
51	15

Table 4. Prior Percutaneous Transluminal Mitral Commissurotomy (PTMC)

Yes	No
12	54

4. DISCUSSION

Pregnancy is characterized by a hyper dynamic state with significant change of hemodynamic especially between the 24th and 26th week of gestation and can explain decompensation in pregnant women with critical mitral stenosis [1,3] However, most patients respond well to adequate medical therapy. In some cases, maximal clinical therapy is not enough and an invasive intervention is required. Surgical mitral commissarotomy was performed during pregnancy with precautions mainly due to the high mortality rates of mother and neonates. [15,17,18] Percutaneous mitral valvuloplasty was first performed in 1984. PTMC proved a safe procedure with outstanding results. However, studies with proper follow-up have not yet been fully described. The present study shows an excellent outcome for the patients after PTMC. After the successful procedure, most of the patients were in Functional Class I or II. In addition, there were no deaths related to the procedure. Echo cardiographic examinations also showed favourable results, with a significant

increase in mitral valve area and decrease in transmitral gradient shortly after the procedure [16]. Only one case of severe mitral regurgitation was observed. The excellent results observed after PTMC in this study can be attributed to the young age of the group and suitable mitral valve morphology. These parameters are both important predictors of short and long term results [17,19]. There were neither maternal nor fetal deaths directly related to the procedure. No fetal abnormalities were found during examination and no clinical abnormalities could be associated with the use of radiation. Concerning the radiation exposure, the maximum safe radiation dose for the mother and the child has been established as 5 rads. Similar fluoroscopy time and the same protection used in other series, reported the total amount of received radiation to be approximately 0.5 rads, therefore far below the established limit. In summary, due to the favorable results observed, percutaneous mitral valvuloplasty can be considered the procedure of choice to treat pregnant women with mitral stenosis unresponsive to adequate medical therapy [16].

Table 5. Procedural indices

Index	Pre procedure	Post procedure	P value
Mitral Valve Orifice area (MVOA)	0.83 ± 0.14	1.39 ± 0.29	0.007
Mitral valve mean Gradient	15.55 ± 7.41	3.36 ± 2.36	0.001
Pulmonary artery pressure	65.24 ± 17.9	50.45 ± 15.33	0.012
Left atrial pressure	28.3 ± 7.2	15 ± 5.45	0.01
Left ventricular ejection fraction	51.97 ± 5.99	51.82 ± 5.7	
No Mitral regurgitation	24 (15.8%)	13 (8.5%)	0.005
Mild Mitral regurgitation	36 (23.7%)	40 (24%)	0.006
Moderate Mitral regurgitation	6 (4%)	12 (7.9%)	0.07
Severe Mitral regurgitation	-	1 (0.6%)	0.04

Table 6. Changes in functional capacity

New York Heart Association (NYHA) Class	0	I	II	III	IV	P value
PRE PTMC	-	2	24	30	10	<0.001
POST PTMC	15	38	11	2		

5. CONCLUSION

The present study shows a favorable immediate outcomes with BMV for gestational woman with symptomatic severe mitral stenosis [16].

CONSENT

As per international standard or university standard written patient consent has been collected and preserved by the author(s).

ETHICAL APPROVAL

The study was approved by ethical committee.

COMPETING INTERESTS

Authors have declared that no competing interests exist.

REFERENCES

1. Glantz JC, Pomerantz RM, Cunningham MJ, Woods JR Jr. Percutaneous balloon valvuloplasty for severe mitral stenosis during pregnancy: A review of therapeutic options. *Obstet. Gynecol. Surv.* 1993; 48(7):503–8.
2. Wong MC, Clark DJ, Horrigan MC, Grube E, Matalanis G, Farouque HM. Advances in percutaneous treatment for adult valvular heart disease. *Intern Med J.* 2009; 39(7):465–74.
3. Mangione JA, Lourenço RM, dos Santos ES, et al. Long-term follow-up of pregnant women after percutaneous mitral valvuloplasty. *Catheter Cardiovasc. Interv.* 2000;50(4):413–7.
4. Zitnik RS, Brandenburg RO, Sheldon R, Wallace RB. Pregnancy and open heart surgery. *Circulation.* 1969;39(Suppl I):257–62.
5. Szekely P, Snaith L. Maternal mortality in rheumatic heart disease. In: Szekely P, Snaith L, editors. *Heart disease and pregnancy.* Edinburg: Churchill Livingstone. 1974;P129–33.
6. Ueland K, Nory MK, Peterson EN, et al. Maternal cardiovascular dynamics: The influence of gestational age on the maternal cardiovascular response to posture and exercise. *Am J. Obstet. Gynec.* 1969;104:856–67.
7. Walters WAW, MacGregor WG, Hills N. Cardiac output at rest during pregnancy and puerperium. *Clin Sci.* 1966;30:1.
8. Stephen SJ. Changing patterns of mitral stenosis in childhood and pregnancy in Sri Lanka. *J Am Coll. Cardiol.* 1992;19:1276–84.
9. Knapp RC, Ardin LI. Closed mitral valvotomy in pregnancy. *Clin Obstet. Gynecol.* 1968;11:978–91.
10. Inoue K, Owaki T, Nakamura T, Kitamura F, Miyamoto N. Clinical application of transvenous mitral commissurotomy by a new balloon catheter. *J. Thorac. Cardiovasc. Surg.* 1984;87:394–402.
11. Gurcharan S, et al. Percutaneous mitral commissurotomy for severe mitral stenosis during pregnancy. *Cathet. Cardiovasc. Diagn.* 1994;33:28–33.
12. Palacios IG, Block PC, Wilkins T, Rediker DE, Daggett W. Percutaneous mitral

- balloon valvotomy during pregnancy in a patient with severe mitralstenosis. *Cathet Cardiovasc. Diagn.* 1988;15:109–11.
13. Safian RD, Berman A, Sachs B, et al. Percutaneous balloon mitral valvuloplasty in a pregnant woman with mitral stenosis. *Cathet Cardiovasc Diagn.*1988;15:103–8.
 14. Esteves CA, Ramos AIO, Braga SLN, Harrison JK, Sousa JEMR. Effectiveness of percutaneous balloon mitral valvotomy during pregnancy. *Am J Cardiol.* 1991; 68:930–4.
 15. Mangione JA, Zuliani MFM, Del Castillo JM, Nogueira EA, Arie S. Percutaneous double balloon mitral valvuloplasty in pregnant women. *Am J. Cardiol.* 1989; 64:99–102.
 16. Abdi S, Salehi N, Ghodsi B, Basiri HA, Momtahn M, Firouzi A, Chamanian S. Immediate results of percutaneous transluminal mitral commissurotomy in pregnant women with severe mitral stenosis. *Clinical Medicine Insights: Cardiology.* 2012;6: CMC-S8580.
 17. Farhat MB, Gamra H, Betbout F, et al. Percutaneous balloon mitral commissurotomy during pregnancy. *Heart.* 1997;77: 564–7.
 18. Munt B, Webb J. Percutaneous valve repair and replacement techniques. *Heart.* 2006;92:1369–72.
 19. Fawzy ME, Kinsara AJ, Stefadourous M, et al. Long-term outcome of mitral balloon valvotomy in pregnant women. *J Heart Valve Dis.* 2001;10:153–7.

© 2020 Anandan et al.; This is an Open Access article distributed under the terms of the Creative Commons Attribution License (<http://creativecommons.org/licenses/by/4.0>), which permits unrestricted use, distribution, and reproduction in any medium, provided the original work is properly cited.

Peer-review history:
The peer review history for this paper can be accessed here:
<http://www.sdiarticle4.com/review-history/53614>