

A Multidisciplinary Technique Using Endonasal Endoscopic Approach with Intrathecal Fluorescein Under Neuronavigation Guidance in Patients with Cerebrospinal Fluid Leak

Afsoun Seddighi, Amir Nikouei, Amir Saied Seddighi

Functional Neurosurgery Research Center, Shahid Beheshti University of Medical Sciences, Tehran, Iran

ABSTRACT

Background: Cerebrospinal fluid (CSF) is contained in an anatomic space, including cerebral ventricles and subarachnoid spaces and cisterns of brain and spine. Distraction of normal anatomy of any containing parts of this system will result in CSF leakage which could be associated with morbidity and mortality with variable degrees. In this study, we aimed to present 3 patients with history of blunt head trauma, who presented with delayed CSF leak and underwent endonasal endoscopic approach under image guided surgery using neuronavigation system with fluorescein illumination.

Case Presentation: Three patients were referred to neurosurgery department of Shohada Tajrish Hospital with previous history of blunt head trauma, complained from CSF rhinorrhea. They underwent thin slice Computed Tomography scan and received intrathecal fluorescein for better visualization of leakage source under live endonasal endoscopic approach, using image guided neuronavigation technology. Autologous fat tissue and fascia was used to seal the leakage site. Clinical and imaging follow up at post-operative state as well as 1st, 2nd, 4th and 8th week revealed no post-operative complications and repeated CSF leakage.

Conclusion: CSF rhinorrhea indicates abnormality in bony structure of skull base and is a major threat for ascending microbial infections and subsequent meningitis. Thus, identification of leakage site(s) and accurate surgical repair is necessary. We experienced a multidisciplinary approach which showed excellent results and no post-operative complications. Multidisciplinary approach with combination of endonasal endoscopic view under neuronavigation system improves accuracy and will minimize post-operative complications.

Keywords: Cerebrospinal fluid leak; Skull base fracture; Intrathecal fluorescein; Endonasal endoscopic approach; Neuronavigation

ICNSJ 2017; 4 (3) :113-117

www.journals.sbmu.ac.ir/neuroscience

Correspondence to: Amir Saied Seddighi, MD, Comprehensive Neurosurgical Center of Excellence, Functional Neurosurgery Research Center, Shahid Beheshti University of Medical Sciences, Tehran, Iran; Tel: +98(912) 2151591; E-mail: A_seddighi@sbmu.ac.ir

Received: April 12, 2017

Accepted: May 8, 2017

INTRODUCTION

Cerebrospinal fluid (CSF) is contained in an anatomic space, including cerebral ventricles and subarachnoid spaces and cisterns of brain and spine. Traditionally, most of CSF production is assumed to be from choroid

plexus, a floating tissue in CSF of lateral, third and fourth ventricles. It has been shown that the brain parenchyma is the other major source in CSF production¹. In 1926, Cushing introduced “third circulation” concept, stating that CSF flows through the ventricles and cisterns and

subarachnoid space, and is reabsorbed to the venous blood stream at arachnoid villi². Also, it has been shown that minor volumes of CSF may be drained into cervical lymphatic stream that run via perineural spaces of the cranial nerves³. Distraction of normal anatomy of any containing parts of this system will result in CSF leakage which could be associated with morbidity and mortality with variable degrees. Bone erosion due to invasive tumor in skull base and congenital abnormalities in this site, as well as increased intracranial pressure (ICP) are among non-traumatic causes of CSF leak. Penetrating and blunt head traumas, as well as skull base fracture as a result of direct blow to related anatomical structures and neurosurgical procedures are categorized as traumatic causes of CSF leak⁴. Both conservative and surgical methods are available for management of CSF leaks in individual directed manner. In this series we aim to describe 3 patients who suffered from CSF leakage due to traumatic skull base fracture who presented with rhinorrhea and underwent intrathecal fluorescein injection and endonasal endoscopic approach with under image guided neuronavigation technology.

CASE PRESENTATION

Three patients were referred to neurosurgery department of Shohada Tajrish Hospital, all complaining

of rhinorrhea with clear appearance and a history of blunt head trauma. Case number 1 was 29-year-old female, with blunt head trauma in car accident from 2 months ago, who presented with left sided rhinorrhea (Figure 1). Case number 2 was a 42-year-old female with a history of skull base fracture in multiple trauma setting who complained from bilateral rhinorrhea (Figure 2). Case number 3 was a 35-year-old female, who presented with left sided rhinorrhea and positive history of blunt head trauma from 5 years ago (Figure 3). All three cases underwent Computed Tomography (CT) scan for detection of possible leakage site from skull bony structures. After thorough evaluation of clinical and imaging features of patients, they underwent thin slice CT scan compatible with image guided neuronavigation application, and received intrathecal fluorescein prior to surgery, for accurate identification of CSF leak site through live endonasal endoscopic approach under neuronavigation guidance. Leak sites were sealed with autologous fat tissue and fascia, along with fibrin glue. Post-operative CT scan revealed no surgery related defect and clinical follow up at 1st, 2nd, 4th and 8th week revealed no surgery related complications and continuance of CSF leakage. Written informed consents were obtained from patients with ethical approval by Ethics Committee of Shohada Tajrish Hospital under the principles of the Helsinki Declaration.

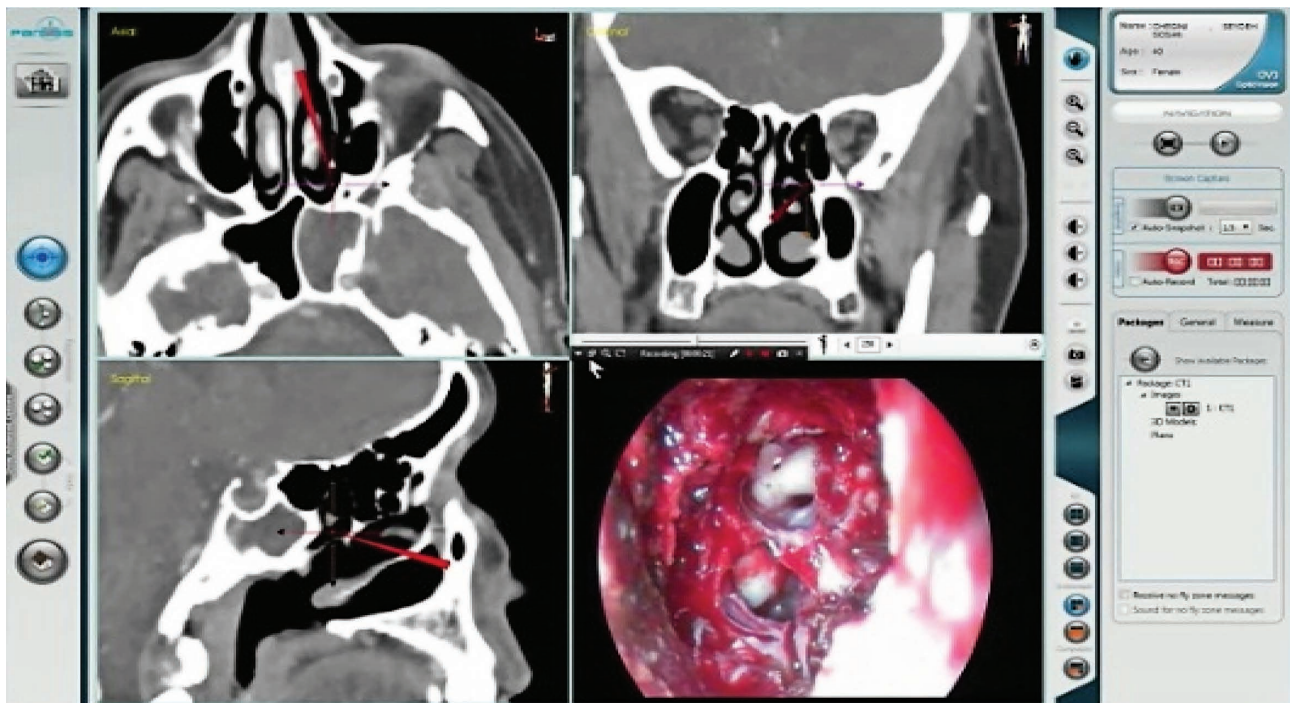


Figure 1. Intra-operative view shows the lateral recess leak site.

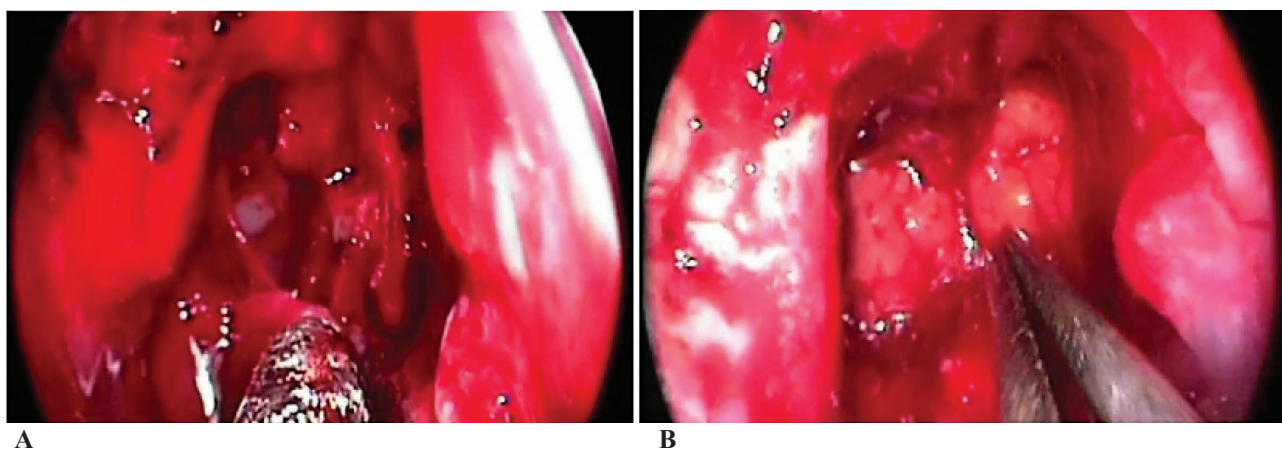


Figure 2. Intra-operative view shows sellar leak site (A) that sealed with fat graft (B).

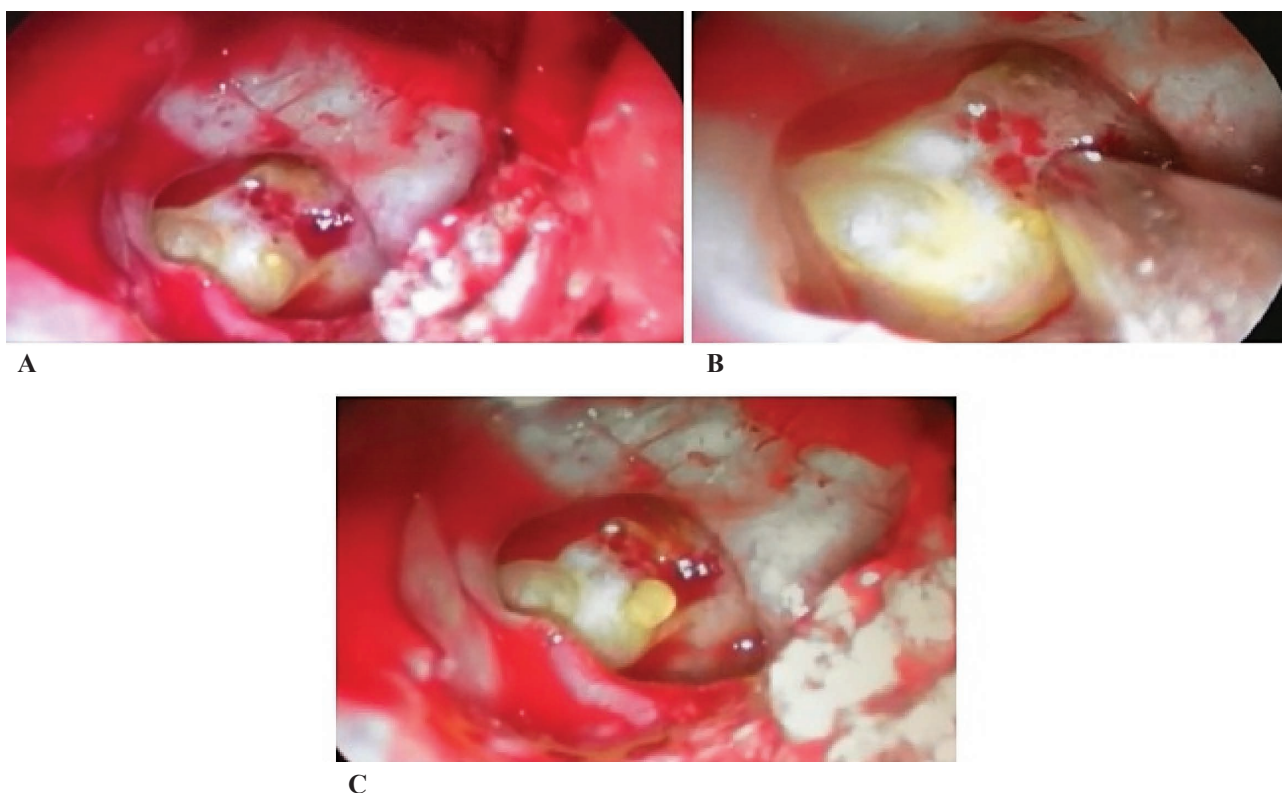


Figure 3. Intra-operative view shows the infra-sellar (Clival area) leak site sealed by fat graft. Carotid recess (A). Skull base bony defect in Clival area (B). Intra-operative view of CSF leak which increased by Valsalva maneuver (C).

DISCUSSION

At first, Galen described CSF leak as a periodic release of fluid into the nasal cavity via sellar region⁵. The midface is anchored to the cranium through a rigid framework called Buttress system, which is shaped by frontal, maxillary, zygomatic and sphenoid bones and their attachment to one another. The Buttress system is responsible for absorption and transmission of applied forces to the craniofacial skeleton⁶. Traumatic events

such as penetrating and blunt head injuries are responsible for most of the CSF leakage caused by disruption of above mentioned bony structures. Due to the firm adherence of the dura to the anterior skull base, CSF leaks from this site are more common than middle and posterior leakages.

The most common sites of CSF rhinorrhea are from fracture lines in sphenoid and frontal sinuses, followed by ethmoid and cribriform sites. Also, temporal bone fractures may result in CSF rhinorrhea through Eustachian tube

in cases of un-ruptured tympanic membrane⁷. Surgical procedures and non-traumatic events are among less common etiologies of CSF leak; however, frequency of CSF leakage due to neurosurgical procedures is increasing in recent years⁸. Idiopathic intracranial hypertension is increasingly recognized as a cause of spontaneous CSF leakage in non-traumatic settings⁹. Traumatic skull base fractures may present as otorrhea, rhinorrhea, Battle's sign, raccoon's eye and cranial nerve lesions. More than 80% of post-traumatic CSF leaks are of post-traumatic rhinorrhea, which most of them will stop on their own, within 1 week. However, delayed leakages may happen months or years later, as in our presented cases. Dural scar formation after traumatic event will seal leakage site in most of the patients; however, it is not a definite barrier against microbial hosts in adjacent paranasal sinuses and nasal cavity. Thus, meningitis risk always threatens patients who suffered from CSF leakage and within first days of disappearance of rhinorrhea¹⁰. Micro-traumas and dural tissue atrophy are two major causative agents responsible for repeated CSF leakage. The most common presentation of CSF leak is unilateral clear watery rhinorrhea, often with salty or sweet taste, and its volume depends on positional status of the patient¹¹.

Traditionally, visualization of a halo sign on gauze has been used to predict CSF leak following head trauma. Meurman et al discovered β 2-transferrin as a highly sensitive and specific marker for CSF¹². Nowadays, detection of β -trace protein (β TP) which is produced by the meninges and choroid plexus has 100% sensitivity and specificity for CSF¹³. High resolution CT scan, intrathecal fluorescein injection, CT cisternography, radionuclide cisternography, Magnetic Resonance Imaging and cisternography are among available diagnostic imaging modalities for identification of CSF leak site¹⁴.

Conservative management of these patients is directed to decrease the volume of leaking CSF, avoid maneuvers that could increase ICP, head elevation to 30 degrees and strict blood pressure control to avoid raised cerebral blood flow and subsequent increase in ICP. In addition, CSF diversion by lumbar drain with average drainage of 10 mL per hour is performed in cases with persistent CSF leak. Possible complications include headache, pneumocephalus and meningitis¹⁵. The first surgical management was conducted by Dandy in 1926, who performed transcranial approach by using a bi-frontal craniotomy¹⁶. Extra-cranial and trans-nasal approaches were developed later. Wigand et al performed the first endonasal endoscopic approach in 1981¹⁷.

In this experience, authors utilized a combination of

intrathecal fluorescein for accurate localization of CSF leak under live endonasal endoscopic approach, combined with image guided surgery using neuronavigation system, for improvement of anatomical understanding and decrease failure rate and avoid possible post-operative complications, which was not observed in our presented cases^{18,19}. Based on our experience, we suggest a multidisciplinary approach to maximize defect closure accuracy and prevention of possible post-operative complications and repeated CSF leak after operation.

CONCLUSION

Abrupt identification of skull base bony defects (macroscopic and microscopic) is essential as it is a well known source of ascending microorganisms capable of meningeal infection and associated morbidities. CSF leak site recognition and skull base defect reconstruction by a multidisciplinary approach with combination of endonasal endoscopic view under neuronavigation system improves precision and will minimize post-operative complications and could be considered as a method of choice for complicated cases with previous history of multiple failed reconstruction.

REFERENCES

1. Milhorat TH. The third circulation revisited. *J Neurosurg.* 1975;42(6):628-45.
2. Williams MA, Razumovsky AY. Cerebrospinal fluid circulation, cerebral edema, and intracranial pressure. *Current Opin Neurol.* 1993;6(6):847-53.
3. Brinker T, Stopa E, Morrison J, Klinge P. A new look at cerebrospinal fluid circulation. *Fluids Barriers CNS.* 2014;11(1):10.
4. Yang Z, Wang B, Wang C, Liu P. Primary spontaneous cerebrospinal fluid rhinorrhea: a symptom of idiopathic intracranial hypertension? *J Neurosurg.* 2011;115(1):165-70.
5. Zlab MK, Moore GF, Daly DT, Yonkers AJ. Cerebrospinal fluid rhinorrhea: a review of the literature. *Ear Nose Throat J.* 1992;71(7):314-7.
6. Bluebond-Langner R, Rodriguez ED. Application of skeletal buttress analogy in composite facial reconstruction. *Craniofac Trauma Reconstr.* 2009;2(01):019-25.
7. Banks CA, Palmer JN, Chiu AG, O'malley BW, Woodworth BA, Kennedy DW. Endoscopic closure of CSF rhinorrhea: 193 cases over 21 years. *Otolaryngol Head Neck Sur.* 2009;140(6):826-33.
8. Olabinri EO, Ogbole GI, Adeleye AO, Dairo DM, Malomo AO, Ogunseyinde AO. Comparative analysis of clinical and computed tomography features of basal skull fractures in head injury in southwestern Nigeria. *J Neurosci Rural Pract.* 2015;6(2):139.

9. Pérez MA, Bialer OY, Bruce BB, Newman NJ, Biousse V. Primary spontaneous cerebrospinal fluid leaks and idiopathic intracranial hypertension. *J Neuroophthalmol*. 2013;33(4):330.
10. Schick B, Weber R, Kahle G, Draf W, Lackmann GM. Late manifestations of traumatic lesions of the anterior skull base. *Skull Base*. 1997;7(02):77-83.
11. Ohwaki K, Yano E, Ishii T, Takanashi S, Nakagomi T. Symptom predictors of cerebrospinal fluid leaks. *Can J Neurol Sci*. 2008;35(04):452-7.
12. Mantur M, Łukaszewicz-Zajac M, Mroczko B, Kułakowska A, Ganslandt O, Kemoni H, et al. Cerebrospinal fluid leakage—Reliable diagnostic methods. *Clin Chim Acta*. 2011;412(11):837-40.
13. Arrer E, Meco C, Oberascher G, Piotrowski W, Albegger K, Patsch W. β -Trace protein as a marker for cerebrospinal fluid rhinorrhea. *Clin Chem*. 2002;48(6):939-41.
14. Arjmand Y, Torkian P, Keipourfard A. Radiologic Evaluation of Patients with Glioblastoma Multiforme who Initially Presented with Ischemic Stroke: A Case Series. *American Journal of Medical Case Reports*. 2017;5(1):8-11.
15. Mostafa BE, Khafagi A, Morcos JJ. Combined HRCT and MRI in the detection of CSF rhinorrhea. *Skull Base*. 2004;14(03):157-62.
16. Dandy WE. Pneumocephalus (intracranial pneumocele or arocele). *Arch Surg*. 1926;12:949–82.
17. Wigand ME. Transnasal ethmoidectomy under endoscopic control. *Rhinology*. 1981;19(1):7-15.
18. Nikouei A, Seddighi A, Seddighi AS. The Results of Image Guided Surgery Using Neuronavigation in Resection of Cerebral Gliomas in Eloquent Cortical Areas. *Arch Phys Med Rehabil*. 2016;97(10):e69-70.
19. Seddighi A, Seddighi AS, Nikouei A, Mohseni G. NS-06 Image Guided Surgery Using Neuronavigation System in Resection of Cerebral Gliomas Involving Eloquent Cortical Areas in Pediatric Population. *Neuro Oncol*. 2016;18(suppl 3):iii128-.