

# Refractory Hypoglycaemia in Hepatocellular Carcinoma Treated with TACE Leading to Tumour Lysis Syndrome- A Double Trouble

SAURABH KUMAR<sup>1</sup>, ISHITA B SEN<sup>2</sup>, VIVEK VIJ<sup>3</sup>, ASHISH SINGHAL<sup>4</sup>, AJITABH SRIVASTAVA<sup>5</sup>

CC BY-NC-ND

## ABSTRACT

Hepatocellular Carcinoma (HCC) is the most common type of primary liver cancer. Hypoglycaemia is a well-established paraneoplastic manifestation of HCC. Cyto-reduction by surgery or Transarterial Chemoembolisation (TACE) has been effective treatment options in such cases when conservative treatment fails. Tumour Lysis Syndrome (TLS) is an oncological emergency following treatment of malignancies with high cell turnover and can be seen in liver-directed therapy in the form of both ablative therapies and transarterial therapies for HCC. Authors present a rare case of 65-year-old male, with HCC presented with symptoms of refractory hypoglycaemia which was managed by TACE procedure with further patient developing TLS which was medically managed.

**Keywords:** Cyto-reduction, Hepatomegaly, Transarterial chemoembolisation

## CASE REPORT

A 65-year-old male known case of Hepatitis C virus related cirrhosis with Hepatocellular Carcinoma (HCC) presented with dizziness and incoherent speech in emergency. The patient was found to have a blood glucose level of 30 mg/dL and was treated with dextrose infusion to which the patient partially responded.

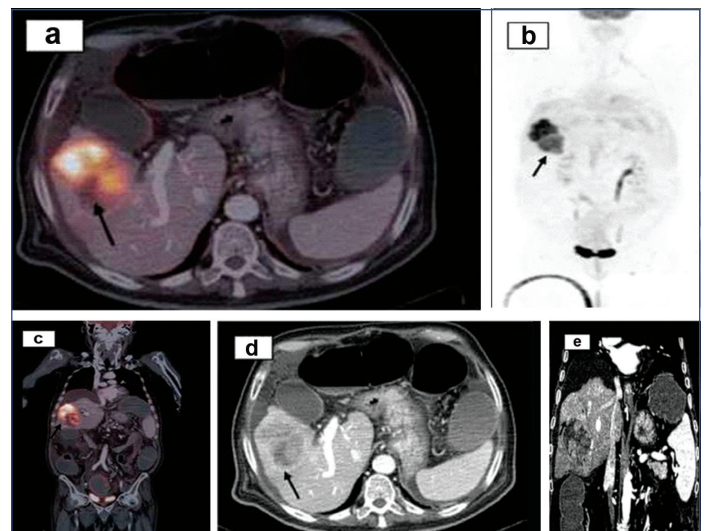
Physical examination revealed hepatomegaly with laboratory reports suggestive of Child- Pugh B liver disease {total bilirubin was 1.1 mg/dL, International Normalised Ratio (INR) was 1.45, serum albumin was 3 gm/dL, mild ascites}. Serum Alpha Fetoprotein (AFP) was markedly raised (33000 ng/mL). Infectious aetiology for patient's hypoglycaemia was ruled out by haematological workup, urinalysis, stool culture and chest X-ray.

Positron Emission Tomography (PET), with triple phase Computed Tomography (CT) liver, with fluorine-18-Fluorodeoxyglucose (18-FDG) was performed rather than triple phase CT or Magnetic Resonance Imaging (MRI) to rule out metastatic disease. It revealed large (>10 cm) arterial enhancing hypermetabolic bilobulated mass lesion involving right lobe of liver (segment 5,7) showing areas of cystic necrosis inferiorly and venous/delayed phase washout consistent with the diagnosis of HCC [Table/Fig-1a,b]. No associated portal vein thrombus noted. High uptake index suggested of an elevated glucose consumption tumour. Rest of scan showed no evidence of locoregional or distal metastasis [Table/Fig-1c-e].

To further investigate cause of persistent hypoglycaemia haematological investigation revealed insulin level of 0.30 mIU/mL {Normal Range (NR) 2.6-24.9}, and the C-peptide level was 0.4 ng/mL (NR 1.1-4.4), suggesting a non islet cell aetiology of hypoglycaemia. Insulin-like Growth Factor-1 (IGF-1) was suppressed {20 ng/mL (NR 49-214 ng/mL)}, IGF-2 was in upper range normal {950 ng/mL (NR 300-960 ng/mL)} and elevated IGF-2/IGF-1 ratio (>10), consistent with the diagnosis of Non Islet Cell Tumour Paraneoplastic Hypoglycaemia (NICTH).

The patient continued requiring 20% dextrose infusion and high-dose prednisone to maintain euglycaemic status. Transarterial Chemoembolisation (TACE) was then considered as palliative therapy for his refractory hypoglycaemia as patient was not a candidate for transplantation and surgical resection due to large tumour burden and liver disease status.

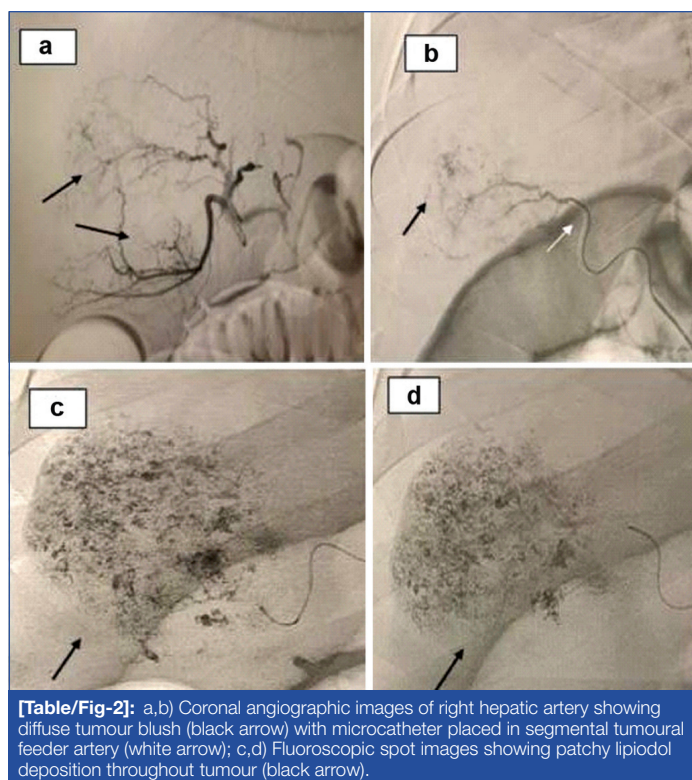
Chemoembolisation {Conventional TACE (cTACE)} was performed from the right hepatic artery [Table/Fig-2a] with epirubicin (70 mg) and Lipiodol (15 mL) injected through microcatheter (progreat 2.7 Fr)



**[Table/Fig-1]:** a,b,c) Positron Emission Tomography and Computed Tomography (PET-CT) images (axial and coronal) showing hypermetabolic avid mass in right lobe of liver (black arrow); d, e) Corresponding axial and coronal CECT images showing heterogeneously enhancing mass lesion in right lobe liver with non enhancing necrotic areas inferiorly (black arrow).

[Table/Fig-2b] placed in segmental branches close to tumour. Embolisation was completed with gelfoam when near-stasis of flow was achieved. Postembolisation patchy complete lipiodol deposition in the tumour noted [Table/Fig-2c,d]. Postembolisation hepatic function were within normal range including a serum bilirubin level of 1.5 mg/dL, alkaline phosphatase level of 400 IU/L, aspartate aminotransferase level of 110 IU/L, and alanine aminotransferase level of 60 IU/L. After the embolisation there is significant drop (>95%) in dextrose requirement within 24 hours.

On the second day after the TACE procedure, the patient becomes disoriented despite euglycaemic status and had to be intubated due to falling oxygen saturation level secondary to aspiration. The levels potassium (6.5 mmol/L), magnesium (10 mg/dL), uric acid (9.1 mg/dL), and phosphate (6.2 mg/dL) were all elevated with mild derangement of renal parameters (blood urea nitrogen 70 mg/dL and creatinine 2 mg). The liver function were within normal range with stable bilirubin level so post TACE liver decompensation or failure was ruled out. Thus, possibility of TLS was strongly suspected. Hydration by intravenous fluid infusion was started with intravenous allopurinol, calcium gluconate, insulin with dextrose and urine



**[Table/Fig-2]:** a,b) Coronal angiographic images of right hepatic artery showing diffuse tumour blush (black arrow) with microcatheter placed in segmental tumoural feeder artery (white arrow); c,d) Fluoroscopic spot images showing patchy lipiodol deposition throughout tumour (black arrow).

alkalisation. There is gradual improvement in patient's renal function with correction of metabolic abnormalities except serum magnesium which was persistently high. There was no significant improvement in patient mental status. So, the patient was put on haemodialysis for hypermagnesemia. Gradually over a period of 10 days the serum magnesium level became normal with improvement in patient mental status and patient was put off mechanical ventilation and haemodialysis. Serum AFP level in third week decrease down to 3000 (baseline 33000 ng/mL) suggestive of good response to TACE. Patient was further advised follow-up imaging at six weeks however, he was lost to follow-up.

## DISCUSSION

Hypoglycaemia in HCC patients can be of two types [1]. Type A hypoglycaemia which is seen in later course of disease in rapidly growing tumours with associated significant muscle wasting due to inability of the liver to satisfy glucose demands of the tumour. Type B 2 hypoglycaemia or paraneoplastic hypoglycaemia which manifest early in the course of disease (as seen in the present case) with high IGF-II level produced by tumours, resulting in stimulation of the insulin receptors and increased glucose utilisation and associated decrease serum insulin and C-peptide level. HCC patients with paraneoplastic manifestations have decreased survival independent of tumour size and extent [2,3].

Treatment options for non islet cell tumour hypoglycaemia are directed to control tumour metabolic activity with either surgical resection or cytoreduction, with supportive dextrose and

glucocorticoid administration [3,4]. Surgical resection is difficult or impossible, as large tumours are often unresectable (as seen in present case) and patients have associated advance liver disease. TACE when appropriately selected has been used in those with HCC-induced hypoglycaemia with good outcomes [5].

The TLS results from either spontaneous or chemotherapy-induced tumour cell death with rapid amount of cellular destruction [6]. It releases intracellular contents and electrolytes into the systemic circulation and lead to development of hyperuricaemia, hyperphosphatemia, hypocalcaemia, and hyperkalemia and hypermagnesemia. Clinically, it can lead to acute kidney injury with decrease urine output, cardiac arrhythmia and seizures. TLS is seen in patients with leukaemia, lymphoma, or multiple myeloma on chemotherapy if there is a large amount of disease present [6]. TLS may occur after various treatments of HCC [7], including radiofrequency ablation, oral sorafenib and TACE. Pretreatment risk factors include large tumour size, rapid tumour growth, and renal insufficiency [7]. In the present case, only risk factor of large tumour size was there and TLS was not anticipated before therapy with TACE. Effective treatment for TLS includes adequate hydration, oral medication (allopurinol and/or urate oxidase) or haemodialysis.

In literature review, no such case has been reported in which refractory hypoglycaemia due to HCC and TLS on treatment have been reported in same patient.

## CONCLUSION(S)

The HCC with paraneoplastic manifestation must be considered in a patient with chronic liver disease who presents with refractory hypoglycaemia. Conservative treatment with dextrose and steroids is the recommended treatment option and surgical treatment or TACE is considered in non responders. TLS should always be considered in patients of who develop classical metabolic abnormalities with impaired renal function after any therapy leading to increase tumour cell turnover or cell death. Prompt treatment should be started in such cases and pre treatment risk factors of developing TLS should be always kept in mind before planning any treatment.

## REFERENCES

- [1] Yu B, Douli R, Suarez JA, Gutierrez VP, Aldiabat M, Khan M. Non islet cell tumour hypoglycaemia as an initial presentation of hepatocellular carcinoma coupled with end-stage liver cirrhosis: A case report and review of literature. *World J Hepatol.* 2020;12(8):519-24.
- [2] Forde JJ, Ewelukwa O, Brar T, Cabrera R. Intractable Fasting Hypoglycaemia as a Manifestation of Hepatocellular Carcinoma. *Case Reports Hepatol.* 2017;2017:7465025.
- [3] Nikeghbalian S, Bananzadeh A, Yarmohammadi H. Hypoglycaemia, the first presenting sign of hepatocellular carcinoma. *Saudi Med J.* 2006;27(3):387-88.
- [4] Qu Q, Wang S, Chen S, Zhou L, Rui JA. Prognostic role and significance of paraneoplastic syndromes in hepatocellular carcinoma. *Am Surg.* 2014;80(2):191-96.
- [5] Whitsett M, Lindenmeyer CC, Shaw CM, Civan JM, Fenkel JM. Transarterial chemoembolisation for palliation of paraneoplastic hypoglycaemia in a patient with advanced hepatocellular carcinoma. *J Vasc Interv Radiol.* 2013;24(12):1918-20.
- [6] Cairo M S, Bishop M. Tumour lysis syndrome: New therapeutic strategies and classification. *Br J Haematol.* 2004;127(1):03-11.
- [7] Hsieh P-M, Hung KC, Chen YS. Tumour lysis syndrome after transarterial chemoembolisation of hepatocellular carcinoma: Case reports and literature review. *World J Gastroenterol.* 2009;15(37):4726-28.

### PARTICULARS OF CONTRIBUTORS:

1. Consultant Interventional Radiologist, Department of Interventional Radiology, Fortis Memorial Research Institute, Gurugram, Haryana, India.
2. Director, Department of Nuclear Medicine, Fortis Memorial Research Institute, Gurugram, Haryana, India.
3. Director, Department of Liver Transplant and Hepatobiliary Surgery, Fortis Memorial Research Institute, Gurugram, Haryana, India.
4. Senior Consultant, Department of Liver Transplant and Hepatobiliary Surgery, Fortis Memorial Research Institute, Gurugram, Haryana, India.
5. Senior Consultant, Department of Liver Transplant and Hepatobiliary Surgery, Fortis Memorial Research Institute, Gurugram, Haryana, India.

### NAME, ADDRESS, E-MAIL ID OF THE CORRESPONDING AUTHOR:

Dr. Saurabh Kumar,  
Consultant Interventional Radiologist, Department of Interventional Radiology,  
Fortis Memorial Research Institute, Sector-44, Gurugram, Haryana, India.  
E-mail: sunny\_mamc911@yahoo.com

### AUTHOR DECLARATION:

- Financial or Other Competing Interests: None
- Was informed consent obtained from the subjects involved in the study? Yes
- For any images presented appropriate consent has been obtained from the subjects. Yes

### PLAGIARISM CHECKING METHODS: [Jain H et al.]

- Plagiarism X-checker: Sep 08, 2021
- Manual Googling: Dec 09, 2021
- iThenticate Software: Dec 29, 2021 (9%)

### ETYMOLOGY: Author Origin

Date of Submission: **Sep 07, 2021**  
Date of Peer Review: **Nov 17, 2021**  
Date of Acceptance: **Dec 09, 2021**  
Date of Publishing: **Jan 01, 2022**