

# Effect of Oral Drug Apremilast on Histopathological Changes in Patients of Plaque Psoriasis: A Prospective Observational Study

YOGENDRA SINGH<sup>1</sup>, ASHISH BAGARIA<sup>2</sup>, BHAWNA BAGARIA<sup>3</sup>, YOGESH GUPTA<sup>4</sup>

## ABSTRACT

**Introduction:** Psoriasis is a chronic non infectious recurrent papulosquamous inflammatory disorder characterised by vascular alterations such as angiogenesis, dilatation, increased endothelial venule generation, epidermal keratinocyte hyperproliferation, and aberrant differentiation, and lymphocytic invasion of T-cells. The aetiopathogenesis of disease is influenced by both hereditary and environmental factors. Pathogenesis is significantly influenced by immune dysregulation, which affects both innate and acquired immunity. A relatively recent medication for the management of moderate to severe plaque psoriasis is apremilast, an oral phosphodiesterase-4 inhibitor. Compared to other immune-suppressing drugs used in psoriasis apremilast causes no reactivation of tuberculosis or opportunistic infections, does not need dose adjustment in elderly or patients with hepatic impairment, and is not contraindicated in diabetes, ischaemic heart disease, or congestive cardiac failure. Due to its advantage of the absence of the need for laboratory monitoring, the patients on long-term methotrexate can also be switched to apremilast.

**Aim:** To evaluate the histopathological changes in the skin of all plaque psoriatic patients treated with oral drug apremilast.

**Materials and Methods:** This hospital-based prospective study was done in the Department of Pathology at the Rajasthan

University of Health Sciences (RUHS), Jaipur, India for a period of one year from February 2020 to January 2021 comparing the efficacy of Apremilast clinically by evaluating plaque psoriasis patients' by Psoriasis Area and Severity Index (PASI) scores. Patients of all age groups with a clinical diagnosis of psoriasis were subjected to a punch biopsy from an active lesion by a dermatologist. For histopathological examination, biopsy was taken from the lesion before starting treatment with apremilast and after four weeks of apremilast therapy. The subsequent changes in the form of histopathological score and PASI score were analysed and compared with the previous score to study the effect of oral drug apremilast.

**Results:** Total of 100 patients enrolled in the study with the mean age 39.14 years including 59% males and 41% females. Main site of lesion was back, hand and leg. The PASI score at the first visit was 11.28 and at the second visit were 7.27 with the improvement 35.54% which was statistically significant from first visit (p-value <0.001). The histopathological score at the first visit was 15.98 and at the second visit were 10.06 with the improvement 37.1%.

**Conclusion:** Apremilast was found to be a safe and effective treatment for psoriasis patients, and this impact was unaffected by confounding variables.

**Keywords:** Angiogenesis, Epidermal keratinocytes, Papulosquamous inflammatory disorder, Psoriasis area and severity index score

## INTRODUCTION

People of all ages are affected by the widespread chronic systemic inflammatory skin disease known as psoriasis worldwide. Psoriasis prevalence rates range widely depending on geography, from 0.09-11.4%, and are predicted to be 2-4% in the Western population [1,2]. While the exact cause of the condition is unknown, psoriasis is widely recognised as a significant disorder brought on by the interaction of inherited susceptibility alleles and environmental risk factors known as triggers (such as trauma, viral and bacterial infections, smoking, weight gain, stress as well as alcohol consumption) [3]. Plaque psoriasis is indeed a prevalent type and is distinguished by inflammatory plaques on the skin. Such papulosquamous lesions, which are frequently itchy and/or painful, can develop on both common skin sites like the knees, elbows, scalp, and lumbar region as well as in challenging skin regions like the scalp, nails, palms, and soles of the feet [4]. The overproduction of inflammatory cytokines, which alters the immune response, is one of the disease's key molecular hallmarks. Particularly important are the interleukin IL-12 and IL-23 secreted by myeloid dendritic cells, which stimulate T-helper cells to create IL-17, tumour necrosis factor, interferon, and IL-22. This mechanism causes the keratinocytes to develop

prematurely, leukocytes to infiltrate the dermis, and blood vessels to enlarge, which causes the epidermal layer to hyperproliferate and ultimately form plaques [5]. There are many ways to treat psoriatic disease symptoms for patients with mild disease, topical and/or phototherapies may be used, moreover patients with moderate-to-severe ailment traditional systemic treatment which consist of disease modifying antirheumatic drugs, such as (cyclosporine, fumaric acid esters, methotrexate, retinoids) or modern biologic systemic treatments such as (Ixekizumab, infliximab, ustekinumab, secukinumab, adalimumab) can be used [6]. Long-term treatment is usually necessary due to the chronic nature of psoriatic illness [7]. Dissatisfaction among patients with the available recent therapies often leads to decreased adherence to treatment and as a result, worsening of the illness [8]. This may be the result of declining health status brought on by tolerability challenges, safety issues (such as worries about infection or cancer from biological agents), lack of effectiveness, or loss of efficacy, as well as psychological factors like the mode of administration (difficulties brought on by intravenous or subcutaneous methods of administration) [9].

The US Food and Drug Administration on September 24, 2014, approved the oral phosphodiesterase-4 inhibitor apremilast for the

management of psoriasis. In comparison to biologics and other systemic antipsoriatic medications, it has the benefit of not requiring laboratory monitoring throughout usage and of being administered via the oral route. The medication controls phosphodiesterase-4, which is abundantly expressed in dendritic cells, monocytes, neutrophils, and keratinocytes and prevents the breakdown of cyclic adenosine monophosphate, to control the immune reactions related to psoriasis. Diarrhoea, nasopharyngitis, nausea, upper respiratory infections, and headache are the most commonly mentioned side-effects [10]. Hence, the novelty of this study is that it is conducted to evaluate the clinical efficacy and side-effects of oral apremilast therapy in patients affected by plaque psoriasis.

## MATERIALS AND METHODS

This hospital-based prospective study was done in the Department of Pathology at the RUHS Medical College, Jaipur, Rajasthan, India for a period of one year from February 2020 to January 2021 after receiving approval from the RUHS-Content Management System (CMS) Ethics Committee (IEC no.-EC/P-28/2019). Consent was obtained either from the patient or their guardians, after explaining the procedure in vernacular language.

**Inclusion criteria:** Patients with age >18 years and both gender coming to Outpatient Department (OPD) of Dermatology in Rukmani Devi Beni Parsad Jaipuria Hospital, attached with RUHS-CMS Jaipur, who presented with skin psoriasis and confirmed for psoriasis on histopathological examination were included in the study.

### Exclusion criteria:

- Patients who were non co-operative and did not give consent for punch biopsy.
- Inadequate biopsy samples were defined as those <4 mm in maximum diameter or showing only the epidermis or dermis on histopathological examination.
- Patients diagnosed clinically with any other type of psoriasis other than psoriasis vulgaris.
- Pregnant women.

**Sample size calculation:** All those patients who fulfilled the inclusion and exclusion criteria were the subjects of the proposed study. The average skin punch biopsy specimens referred to the Histopathology Laboratory, Department of Pathology, RUHS Medical College and Jaipuria Hospital were 50 in the previous six months (as per previous records). A study data of one year was collected, therefore, the total number of patients were 100.

## Study Procedure

Patients of all age groups who had a clinical diagnosis of psoriasis were subjected to a punch biopsy from an active lesion by a dermatologist. Punch biopsy of skin was collected from the lesion's margin, placed in a vial with fixative (10% formalin), and sent to the Department of Pathology for tissue processing and histopathological examination. After histopathological confirmation of plaque psoriasis, the patient received treatment with apremilast 30 mg dose once a day for the first 14 days followed by 30 mg dose twice a day for the next 14 days. After the completion of an oral dose of 4 weeks of apremilast, a punch biopsy was repeated from the same lesion. The subsequent variations in the form of the histopathological score and PASI score were examined and compared with the previous score to study the effect of the oral drug apremilast [11].

**Score for the PASI:**  $0.1 (EH+IH+SH)AH+0.2 (EU+IU+SU)AU+0.3 (ET+IT+ST)AT+0.4 (EL+IL+S)AL$

where, A=Area U=Upper Arm L=Legs H=Head T=Trunk  
E=Erythema I=Induration S=Scalling

**Histopathological processing of punch biopsy of skin:** Specimens were fixed in 10% formalin and subsequently processed as per standard technique following that standard methods were used to

cut and stain the paraffin sections with Haematoxylin and Eosin (H&E) (Nuclei-blue, Cytoplasm-pink).

**Reagents used in Haematoxylin and Eosin staining:** Mayer's haematoxylin was used which was reddish brown in color. 1% stock alcoholic eosin from which working eosin solution was prepared as: just before use, 0.5 mL of glacial acetic acid was added to every 100 mL of stain and blended in with the eosin stock solution as one part to three parts alcohol. [Table/Fig-1] shows 10 histopathological features graded according to their prominence. The Psoriasis Histopathologic Score (PHS) is the total of 10 grading scores for each sample. The histopathological score ranges from 0-40. [Table/Fig-2] shows the PASI score which ranges from 0-72 [11].

Histopathological features	Before treatment (Grading score) 0/1/2/3/4	After treatment (Grading score) with Apremilast 0/1/2/3/4
Regular rete ridge elongation		
Dermal papillae lengthening		
A dermal papillae oedema		
Vascular dilation		
Suprapapillary plate thinning		
Recurrent parakeratosis		
Lack of a granular layer		
Lymphocytic perivascular and dermal infiltrates		
Kogoj's spongiform pustules		
Munro's microabscesses		
<b>Final score</b>		
Histopathological features	Grade	
None	0	
Slight	1	
Moderate	2	
Marked	3	
Very differentiated	4	
PASI score	Before treatment	After treatment with apremilast

[Table/Fig-1]: Histopathological features and score.

Histopathological grading:

The Psoriasis Histopathologic Score (PHS) was calculated as the average of 10 grading points for each sample; Histopathological score varies from 0-40; PASI: Psoriasis area and severity index

Area	Head	Arms
	0% <input type="radio"/> <10% <input type="radio"/> 10-29% <input type="radio"/> 30-49% <input type="radio"/> 50-69% <input type="radio"/> 70-89% <input type="radio"/> 90-100% <input type="radio"/>	0% <input type="radio"/> <10% <input type="radio"/> 10-29% <input type="radio"/> 30-49% <input type="radio"/> 50-69% <input type="radio"/> 70-89% <input type="radio"/> 90-100% <input type="radio"/>
Erythema (redness)	0 1 2 3 4	0 1 2 3 4
Induration (thickness)	0 1 2 3 4	0 1 2 3 4
Desquamation (scaling)	0 1 2 3 4	0 1 2 3 4
	Trunk	Legs
	0% <input type="radio"/> <10% <input type="radio"/> 10-29% <input type="radio"/> 30-49% <input type="radio"/> 50-69% <input type="radio"/> 70-89% <input type="radio"/> 90-100% <input type="radio"/>	0% <input type="radio"/> <10% <input type="radio"/> 10-29% <input type="radio"/> 30-49% <input type="radio"/> 50-69% <input type="radio"/> 70-89% <input type="radio"/> 90-100% <input type="radio"/>
Erythema (redness)	0 1 2 3 4	0 1 2 3 4
Induration (thickness)	0 1 2 3 4	0 1 2 3 4
Desquamation (scaling)	0 1 2 3 4	0 1 2 3 4
Name:	<input type="text"/>	
Birth date:	<input type="text"/>	
	(optional)	(optional)

[Table/Fig-2]: Psoriasis Area and Severity Index (PASI) score.

Score for the PASI:  $0.1 (EH+IH+SH)AH+0.2 (EU+IU+SU)AU+0.3 (ET+IT+ST)AT+0.4 (EL+IL+S)AL$  [11]; PASI score varies from 0-72

## STATISTICAL ANALYSIS

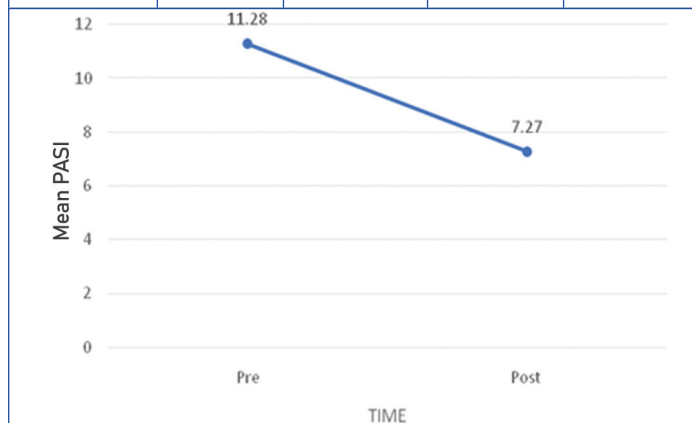
On a predesigned and pretested performa, all the information was compiled. The Microsoft excel sheet 2010 was used to enter the collected data in the form of a master chart. The data was classified and analysed to evaluate the clinical efficacy and side-effects of oral apremilast therapy. Inferences were drawn with the aid of p-value a true test of statistical significance. A p-value <0.05 was considered to be significant.

## RESULTS

This study was done for comparing the efficacy of the drug apremilast clinically by evaluating the PASI score. Total of 100 patients enrolled in the study altogether where 59% was female and 41% male with the mean age 39.14 years. Site of lesion was back, hand and leg. [Table/Fig-3] shows the PASI score at the first visit was 11.28 and at the second visit were 7.27, which showed statistically significant results. [Table/Fig-4] shows the histopathological score at the first visit was 15.98 and at the second visit were 10.06, which showed statistically significant results. [Table/Fig-5] shows Psoriasis vulgaris present on scalp showing white silvery scales involving the hair. [Table/Fig-6] shows Psoriasis vulgaris present on abdomen showing silvery white scales, marked erythema and marked induration. [Table/Fig-7] shows

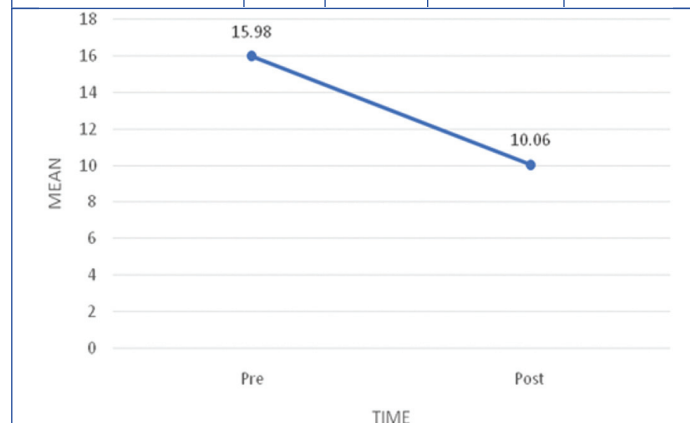
Psoriasis vulgaris present on back showing silvery white scales with crust, erythema and marked induration before treatment. [Table/Fig-8-10] shows skin biopsy performed prior to using apremilast. Psoriasis vulgaris (H&E stain 10x) was seen to have perivascular and dermal lymphocytic infiltration, significant hyperkeratosis, parakeratosis, Munro's microabscesses, lack of granular layer with acanthosis, thinning of suprapapillary plate, regular clubbing and elongation of the rete ridges, oedema of the dermal papillae, and dilated blood vessels near the dermal papillae's tip. [Table/Fig-11-13] shows skin biopsy after treatment with apremilast. Psoriasis vulgaris (H&E stain 10x) showed mild hyperkeratosis, mild parakeratosis, Munro's microabscesses, irregular to regular elongation of rete ridges and clubbing, perivascular and dermal lymphocytic infiltration.

PASI score	Mean	SD	Improvement	p-value
Premedication	11.28	5.05	35.54%	0.001
Postmedication	7.27	3.13		

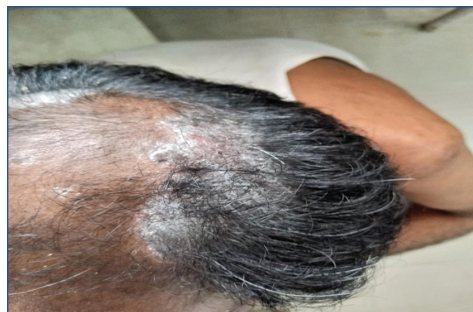

**[Table/Fig-3]:** Comparison of Psoriasis Area and Severity Index (PASI) score. PASI score was 11.28 at the first visit and 7.27 at the second visit which showed statistically significant results; X-axis: Time in days 0-30; Y-axis: Mean in figure from 0-12

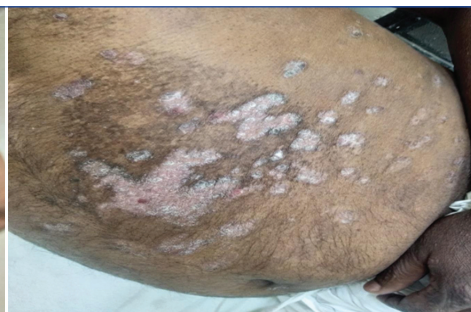Histopathological score	Mean	SD	Improvement	p-value
Premedication	15.98	3.5	37.1%	0.001
Postmedication	10.06	2.06		



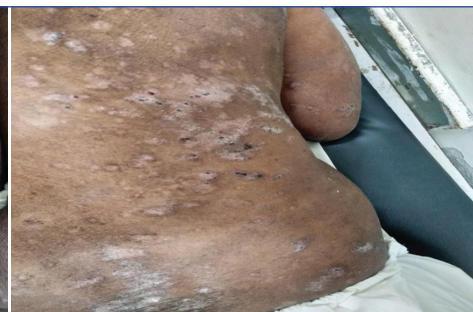**[Table/Fig-4]:** Comparison of histopathological score. Histopathological score was 15.98 at the first visit and 10.06 at the second visit which showed statistically significant results; X Axis: Time in days 0-30; Y Axis: Mean in figure from 0-12



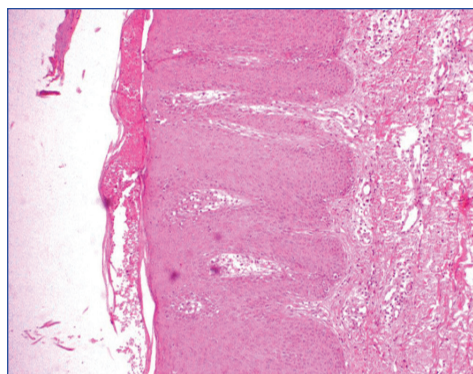
**[Table/Fig-5]:** Psoriasis vulgaris- present on scalp showing white silvery scales.



**[Table/Fig-6]:** Psoriasis vulgaris- present on abdomen showing silvery white scales, marked erythema and marked induration.



**[Table/Fig-7]:** Psoriasis vulgaris- present on back showing silvery white scales, marked erythema and marked induration). (Images from left to right)



**[Table/Fig-8]:** Skin Biopsy before treatment with apremilast.

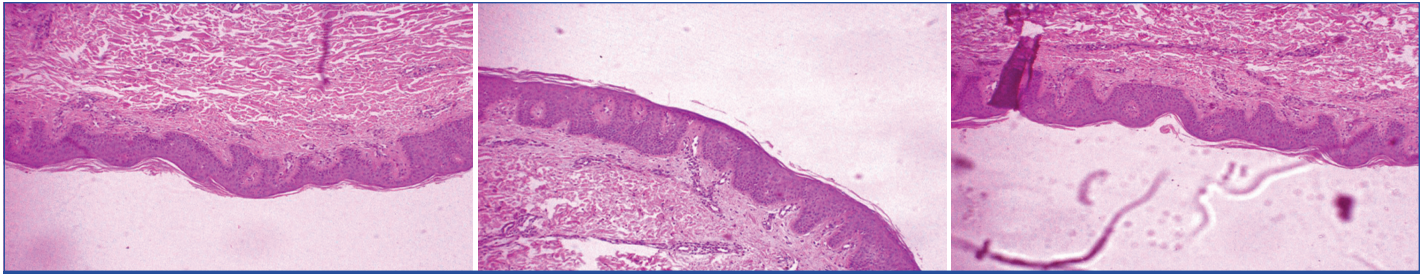
Psoriasis vulgaris- (H&E stain 10x) showing marked hyperkeratosis, parakeratosis, Munro's microabscesses, lack of granular layer with acanthosis, continuous expansion of rete ridges and clubbing, dermal papillae swelling, enlarged blood vessels at the tip of dermal papillae, and dermal and perivascular lymphocytic infiltration were all seen.

**[Table/Fig-9]:** Skin biopsy before treatment with apremilast.

Psoriasis vulgaris- (H&E stain 10x)-showing marked hyperkeratosis, confluent parakeratosis, Munro's microabscesses, lack of granular layer with acanthosis, continuous expansion of rete ridges and clubbing, dermal papillae swelling, enlarged blood vessels at tip of dermal papillae, thinning of suprapapillary plate, perivascular and dermal lymphocytic infiltration seen.

**[Table/Fig-10]:** Skin biopsy before treatment with apremilast.

Psoriasis vulgaris- (H&E stain 10x)-showing marked hyperkeratosis, confluent parakeratosis, Munro's microabscesses, lack of granular layer with acanthosis, continuous expansion of rete ridges and clubbing, dermal papillae swelling, enlarged blood vessels at the tip of dermal papillae, and dermal and perivascular lymphocytic infiltration were all seen. (Images from left to right)



**[Table/Fig-11]:** Skin biopsy after treatment with apremilast.

Psoriasis vulgaris- (H&E stain 10x)-showing mild to moderate hyperkeratosis, mild parakeratosis, Munro's microabscesses, irregular elongation of rete ridges and clubbing, perivascular and dermal lymphocytic infiltration seen.

**[Table/Fig-12]:** Skin biopsy after treatment with Apremilast.

Psoriasis vulgaris- (H&E stain 10x)-showing mild hyperkeratosis, mild parakeratosis, Munro's microabscesses, irregular to regular elongation of rete ridges and clubbing, perivascular and dermal lymphocytic infiltration seen.

**[Table/Fig-13]:** Skin biopsy after treatment with apremilast.

Psoriasis vulgaris- (H&E stain 10x)-showing mild hyperkeratosis, mild parakeratosis, Munro's microabscesses, lack of the granular layer, variable to uniform elongation of the rete ridges, and dermal and perivascular lymphocytic infiltration seen. (Images from left to right)

## DISCUSSION

Food and Drug Administration has approved apremilast as a monotherapy for the treatment of moderate to severely persistent plaque psoriasis in the year 2014 [12]. Non Steroidal Anti-Inflammatory medicines (NSAIDs) and corticosteroids have been used extensively for treating inflammatory diseases for many years, but long-term use of these medications can result in serious organ damage and a number of additional side-effects [13]. There are other compounds, such as apremilast, a phosphodiesterase-4 inhibitor that functions intracellularly, and can regulate immunological dysfunction in addition to biologicals, which do so by suppressing extracellular inflammatory chemicals (extracellular pathways) [14]. Inhibition of the phosphodiesterase-4 inhibitor leads to an increase in the intracellular second messenger cyclic adenosine monophosphate, the activation of the protein kinase A downstream, and the consequent phosphorylation of the transcription factor response element binding protein. When this route is activated, many cytokines have their gene transcription altered, and tumour necrosis factor  $\alpha$  and other proinflammatory cytokines are regulated. Along with interfering with the phenotypic and functionality of B cells, phosphodiesterase-4 inhibitor suppression boosts macrophage production of anti-inflammatory cytokines. By preventing the production of inflammatory mediators, it also promotes keratinocytes and epithelial cells to act as barriers [15]. Because of its significant anti-inflammatory properties, the phosphodiesterase-4 inhibitor apremilast has been looked into for the treatment of many rheumatic diseases, including psoriasis and psoriatic arthritis. Considering its multifactorial nature, psoriasis is a chronic skin inflammation disease that can manifest in a variety of ways. According to various studies, one third of patients have inflammatory spondyloarthropathy psoriatic arthritis in addition to psoriasis, while other patients may have a number of metabolic diseases such as diabetes, obesity, fatty liver disease, cardiovascular diseases and metabolic syndrome [16,17]. Patients have a poorer health-related life quality due to the complexity of the potential manifestations, which causes physical and mental disability [18]. Clinical trials provide the majority of the evidence for apremilast's effectiveness and safety in the treatment of psoriasis and psoriatic arthritis [19]. Because clinical trial patient populations are preselected, actual treatment outcomes may vary from those seen in clinical trials.

In this hospital-based prospective study, the therapeutic effectiveness of apremilast is compared by measuring the PASI score. The score on the PASI improved by 35.54%. The histopathological score showed improvement at a 37.1% rate. In a research conducted by Papp K et al., a greater percentage of patients- 33.1% vs. 17.7% attained a PASI score 75 following roughly 16 weeks of treatment with apremilast [20]. The pathophysiological processes connecting psoriasis to the elevated levels of systemic inflammation brought on by adipose tissue, particularly visceral adipose tissue, which

functions as an endocrine organ and secretes adipokines. Obesity causes an imbalance of pro- and anti-inflammatory adipokines, which leads to the formation of a persistent low grade inflammatory state that may cause or exacerbate psoriasis [21]. Kavanaugh A et al., reported the overall long-term results in individuals with active psoriatic arthritis who used apremilast for up to 260 weeks [22]. According to research, people with psoriatic arthritis who used apremilast continued to see therapeutic benefit and a good safety profile for upto five years. It is also used as a substitute for various drugs such as methotrexate, cyclosporine, and biologicals which have side-effects like increased risk of infections, liver damage, etc., that necessitate regular monitoring. Voorhees ASV et al., determined that inflammation is an evolutionary conservative mechanism that defends the host from viruses, bacteria, poisons, and diseases through stimulation of immune and non immune cells by eradicating pathogens and fostering tissue healing and repair [23]. They observed the effectiveness and safety of apremilast in treating moderate to severe scalp psoriasis. Apremilast significantly increased the number of patients who responded to the scalp physician global assessment (43.3% vs 13.7%), scalp itch numeric rating scales (47.1% vs 21.1%), and whole body itch numeric rating scales (45.5% vs 22.5%) as well as the dermatology life quality index (-6.7 vs -3.8; all p-value < 0.001) when compared to placebo. Treatment of moderate to severe scalp psoriasis with apremilast has been found to be successful. Graier T et al., also found numerous ailments, including cancer, infections, immune-mediated illnesses, and metabolic and neurological diseases, are thought to be primarily brought on by inflammation [24]. They examined as to how patient and illness factors affected survival related to the apremilast medication and clinical effectiveness with relation to the reduction of the PASI score. At 12 months, patients receiving apremilast had response rates per protocol with scores of 50, 75, 90, and 100 on the PASI translate to 80.0%, 56.4%, 38.2%, and 22.7%, respectively. With the exception of age, it was found that apremilast was a potent antipsoriatic medicine whose survival is not significantly influenced by the bulk of patient- or disease-related characteristics. Patients under the age of 40 had considerably shorter drug survival. With the exception of brief gastrointestinal discomfort and headache during the first few weeks, authors have reported a satisfactory safety profile for apremilast. Antacid and antiemetics can be started in advance during dose escalation to help patients experience less nausea and vomiting and to help them tolerate their medications better. With the improvement of lesions at particular body areas like the scalp, palms, and soles, apremilast has a modest level of effectiveness in treating chronic plaque psoriasis. Patients with psoriasis and palmoplantar eczemas may benefit therapeutically from it as well. Although few literature suggests that apremilast is helpful for treating nail psoriasis, this hypothesis still needs to be supported by larger research [25,26].

## Limitation(s)

- Possible recall bias in reporting adverse effects of the patient.
- Long-term follow-up of the patients is required.

## CONCLUSION(S)

Apremilast, is a safe and effective medication for people with psoriasis, which shows better improvement in PASI score as well as histopathological score. It is also a safe alternative for patients with immunological suppression, such as those with HIV. Apremilast reportedly improves the symptoms of ulcerative colitis and is supposed to lessen colon inflammation. When combined with a systemic medication like methotrexate or cyclosporine, it can be used as a maintenance or bridge therapy for people who frequently experience flare-ups. When used strategically as an adjunctive or rotational therapy beside biologics and traditional systemic treatments for psoriasis in low resource settings, this relatively effective chemical with a limited need for laboratory testing can reduce treatment costs, side-effects, and improve outcomes.

## REFERENCES

- [1] Parisi R, Symmons DP, Griffiths CE, Ashcroft DM. Identification and Management of Psoriasis and Associated Comorbidity (IMPACT) project team. Global epidemiology of psoriasis: A systematic review of incidence and prevalence. *J Invest Dermatol.* 2013;133(2):377-85.
- [2] Michalek IM, Loring B, John SM. A systematic review of worldwide epidemiology of psoriasis. *J Eur Acad Dermatol Venereol.* 2017;31(2):205-12.
- [3] Caputo V, Straffella C, Termine A, Dattola A, Mazzilli S, Lanna C, et al. Overview of the molecular determinants contributing to the expression of psoriasis and psoriatic arthritis phenotypes. *J Cell Mol Med.* 2020;24(23):13554-63.
- [4] Vangipuram R, Alikhan A. Apremilast for the management of moderate to severe plaque psoriasis. *Expert Rev Clin Pharmacol.* 2017;10(4):349-60.
- [5] Vujic I, Herman R, Sanlorenzo M, Posch C, Monshi B, Rappersberger K, et al. Apremilast in psoriasis- A prospective real-world study. *J Eur Acad Dermatol Venereol.* 2018;32(2):254-59.
- [6] Keating GM. Apremilast: A review in psoriasis and psoriatic arthritis. *Drugs.* 2017;77(4):459-72.
- [7] Kim WB, Jerome D, Yeung J. Diagnosis and management of psoriasis. *Can Fam Physician.* 2017;63(4):278-85.
- [8] Belinchon I, Rivera R, Blanch C, Comellas M, Lizán L. Adherence, satisfaction and preferences for treatment in patients with psoriasis in the European Union: A systematic review of the literature. *Patient Prefer Adherence.* 2016;10:2357-67.
- [9] Seale L, Cardwell LA, Feldman SR. Adherence to biologics in patients with psoriasis. *Expert Rev Clin Immunol.* 2018;14(2):155-61.
- [10] Armstrong AW, Betts KA, Sundaram M, Thomason D, Signorovitch JE. Comparative efficacy and incremental cost per responder of methotrexate versus apremilast for methotrexate-naïve patients with psoriasis. *J Am Acad Dermatol.* 2016;75(4):740-46.
- [11] Govind B, Mounika C, Reddy JS, Garnepudi K, Reddy VN, Sneha CB. Assessment of quality of life and effectiveness of different therapies in the management of psoriasis at tertiary care hospital in Hyderabad. *World Journal of Pharmaceutical Research.* 2018;7(11):1049-68.
- [12] Shetty VH, Goel S, Babu AM, Eram H. A comparative study of the efficacy and safety of oral Apremilast versus oral methotrexate in patients with moderate to severe chronic plaque psoriasis. *Int J Res Dermatol.* 2018;4(4):563-69.
- [13] AbuHilal M, Walsh S, Shear N. Use of apremilast in combination with other therapies for treatment of chronic plaque psoriasis: A Retrospective study. *J Cutan Med Surg.* 2016;20(4):313-16.
- [14] Hart FD, Huskisson EC. Non-steroidal anti-inflammatory drugs. Current status and rational therapeutic use. *Drugs.* 1984;27(3):232-55.
- [15] Baumgart DC, Misery L, Naeyaert S, Taylor PC. Biological therapies in immune-mediated inflammatory diseases: Can biosimilars reduce access inequities? *Front Pharmacol.* 2019;10:279.
- [16] Carrascosa JM, Bonanad C, Dauden E, Botella R, Oliveira-Martín A; ennombre del Grupo de Trabajo en Inflamación Sistémica en Psoriasis. Psoriasis and nonalcoholic fatty liver disease. *Actas Dermosifiliogr.* 2017;108(6):506-14.
- [17] Masson W, Lobo M, Molinero G. Psoriasis and cardiovascular risk: A comprehensive review. *Adv Ther.* 2020;37(5):2017-33.
- [18] Sendrasoa FA, Razanakoto NH, Ratovonjanahary V, Raharolahy O, Ranaivo IM, Andrianarison M, et al. Quality of life in patients with psoriasis seen in the Department of Dermatology, Antananarivo, Madagascar. *Biomed Res Int.* 2020;2020:9292163.
- [19] Malara G, Trifiro C, Bartolotta A, Giofre C, D'Arrigo G, Testa A, et al. Real-world effectiveness and safety of Guselkumab for the treatment of psoriasis: A 6-month prospective study in a series of psoriatic patients. *Eur Rev Med Pharmacol Sci.* 2021;25(1):406-12.
- [20] Papp K, Reich K, Leonardi CL, Kircik L, Chimenti S, Langley RGB, et al. Apremilast, an oral phosphodiesterase 4 (PDE4) inhibitor, in patients with moderate to severe plaque psoriasis: Results of a phase III, randomized, controlled trial (Efficacy and Safety Trial Evaluating the Effects of apremilast in Psoriasis [ESTEEM] 1). *J Am Acad Dermatol.* 2015;73(1):37-49.
- [21] Henseler T, Christophers E. Psoriasis of early and late onset: Characterisation of two types of psoriasis vulgaris. *J Am Acad Dermatol.* 1985;13(3):450-56.
- [22] Kavanaugh A, Gladman DD, Edwards CJ, Schett G, Guertel B, Nikolay Delev N, et al. Long-term experience with apremilast in patients with psoriatic arthritis: 5-year results from a PALACE 1-3 pooled analysis. *Arthritis Research & Therapy.* 2019;21(1):118.
- [23] Voorhees ASV, Gold LS, Lebwohl M, Strober B, Lynde C, Tyring S, et al. Efficacy and safety of apremilast in patients with moderate to severe plaque psoriasis of the scalp: Results of a phase 3b, multicenter, randomized, placebo-controlled, double-blind study. *J Am Acad Dermatol.* 2020;83(1):96-103.
- [24] Graier T, Weger W, Sator PG, Wolf P. Effectiveness and clinical predictors of drug survival in psoriasis patients receiving apremilast: A registry analysis. *JAAD Int.* 2021;2:62-75.
- [25] Gerosa M, Argolini LM, Artusi C, Chighizola CB. The use of biologics and small molecules in pregnant patients with rheumatic diseases. *Expert Rev Clin Pharmacol.* 2018;11(10):987-88.
- [26] Hoffman MB, Farhangian M, Feldman SR. Psoriasis during pregnancy: Characteristics and important management recommendations. *Expert Rev Clin Immunol.* 2015;11(6):709-20.

### PARTICULARS OF CONTRIBUTORS:

1. Resident, Department of Pathology, Rajasthan University of Health Sciences (RUHS), Jaipur, Rajasthan, India.
2. Associate Professor, Department of Pathology, Sawai Man Singh Medical College (SMSMC), Jaipur, Rajasthan, India.
3. Assistant Professor, Department of Biochemistry, Sawai Man Singh Medical College (SMSMC), Jaipur, Rajasthan, India.
4. Associate Professor, Department of Pathology, Rajasthan University of Health Sciences (RUHS), Jaipur, Rajasthan, India.

### NAME, ADDRESS, E-MAIL ID OF THE CORRESPONDING AUTHOR:

Yogesh Gupta,  
Associate Professor, Department of Pathology, Rajasthan University of Health Sciences (RUHS), Jaipur, Rajasthan, India.  
E-mail: dryogesh.gupta82@gmail.com

### AUTHOR DECLARATION:

- Financial or Other Competing Interests: None
- Was Ethics Committee Approval obtained for this study? Yes
- Was informed consent obtained from the subjects involved in the study? Yes
- For any images presented appropriate consent has been obtained from the subjects. Yes

### PLAGIARISM CHECKING METHODS: [Jain H et al.]

- Plagiarism X-checker: Sep 23, 2022
- Manual Googling: Dec 30, 2022
- iThenticate Software: Jan 06, 2023 (9%)

### ETYMOLOGY: Author Origin

Date of Submission: **Sep 16, 2022**  
Date of Peer Review: **Nov 03, 2022**  
Date of Acceptance: **Jan 10, 2023**  
Date of Publishing: **Mar 01, 2023**