



Case Report of Epstein–Barr Virus (EBV) Meningitis with Arachnoiditis in a Previously Healthy Patient

Somaya A. M. Albhaisi^{1*} and Tehmina Khan²

¹Department of Internal Medicine, Medicine Institute, Sheikh Khalifa Medical City (SKMC), UAE.

²Department of Infectious Disease, Medicine Institute, Sheikh Khalifa Medical City (SKMC), UAE.

Authors' contributions

This work was carried out in collaboration between both authors. Both authors read and approved the final manuscript.

Article Information

DOI: 10.9734/BJMMR/2015/19434

Editor(s):

(1) Renu Gupta, Department of Microbiology, Institute of Human Behaviour and Allied Sciences, New Delhi, India.

Reviewers:

- (1) Anonymous, Tunisia.
(2) A. Martin Lerner, Department of Internal Medicine, Oakland University William Beaumont School of Medicine, USA.
(3) Marcos Antonio Pereira de Lima, Faculty of Medicine, Federal University of Cariri, UFCA, Brazil.
(4) David H. Dreyfus, Department of Pediatrics, Yale School of Medicine and Keren LLC, New Haven CT, USA.
Complete Peer review History: <http://sciencedomain.org/review-history/10552>

Case Study

Received 9th June 2015
Accepted 26th July 2015
Published 14th August 2015

ABSTRACT

Epstein-Barr virus (EBV) is from herpesviridae family that is spread by close contact between susceptible persons and asymptomatic EBV carriers. EBV is the most common causative agent of infectious mononucleosis (IM), that persists asymptotically for life in nearly all adults. It is associated with the development of B cell lymphomas, T cell lymphomas, Hodgkin lymphoma and nasopharyngeal carcinomas in certain patients. EBV is associated with a variety of CNS complications which can occur in the absence of clinical or laboratory manifestations of infectious mononucleosis. EBV meningoencephalitis should always be considered as one of the causative agents in immunocompetent patients who present with clinical features of meningitis. Molecular diagnostic techniques using CSF PCR and blood samples provides prompt diagnosis. Neuroimaging with MRI provides neuroanatomic localization of EBV meningoencephalitis, which may be a prognostic factor. The purpose of this case report is to increase the awareness of health care professionals about EBV meningoencephalitis as an under-diagnosed disease, and emphasize that excellent outcome can be achieved by early treatment. In this case report, we review a young male, with no significant past medical history, who presented with acute EBV meningitis, and was successfully treated medically.

*Corresponding author: Email: somaya_90@hotmail.com;

Keywords: Epstein-Barr virus; EBV Meningoencephalitis; arachnoiditis; immunocompetent.

1. INTRODUCTION

Primary EBV infection frequently results in infectious mononucleosis and, rarely, it produces a chronic active infection. In immunocompromised individuals EBV is associated with nasopharyngeal carcinoma, Burkitt's lymphoma, Hodgkin's disease and lymphoproliferative disease. The molecular, virological and immunological features of EBV have been reviewed [1]. Evidence suggests that increased replication of epigenomic viruses such as EBV in chronic human autoimmune diseases such as rheumatoid arthritis (RA), systemic lupus erythematosus (SLE), and multiple sclerosis (MS) may activate endogenous human retroviruses (HERV) as a pathologic mechanism. Memory B cells are the reservoir of infection of EBV and also express endogenous retroviruses, thus depletion of memory B-lymphocytes by monoclonal antibodies (Rituximab) may have therapeutic anti-viral effects in addition to effects on B-lymphocyte presentation of both EBV and HERV superantigens [2]. The association of neurological disease with IM was first documented 70 years ago and has been extensively reviewed by Gautier-Smith et al. [3]. The incidence of neurological complications due to EBV has been estimated to occur in 1.0–5.0% of individuals with IM. Despite the relatively low frequency of complications, Cerebrospinal fluid (CSF) abnormalities have been found in >25% of cases [4]. Prevalence of EBV infection is high throughout the world, but the burden of neurological disease associated with EBV is probably underestimated. For example, virtually all Central Nervous System (CNS) lymphomas in AIDS (acquired immune deficiency syndrome) patients contain EBV DNA [5]. EBV produces disease of both the CNS and peripheral nervous system. Most of the documentation has been provided by individual case reports of EBV related CNS infections, usually associated with a positive serum heterophile antibody titre. Some reports have also used the finding of EBV antibody in CSF to associate the virus with neuropathy [6], myelitis [7] and encephalitis [8]. For a long time now, polymerase chain reaction (PCR) technology has been used to help diagnose neurological disease produced by herpesviruses [9]. However, because EBV encephalitis is usually not fatal, the site of virus-induced disease in the brain, spinal cord or meninges could not be confirmed until the advent of brain magnetic resonance imaging (MRI).

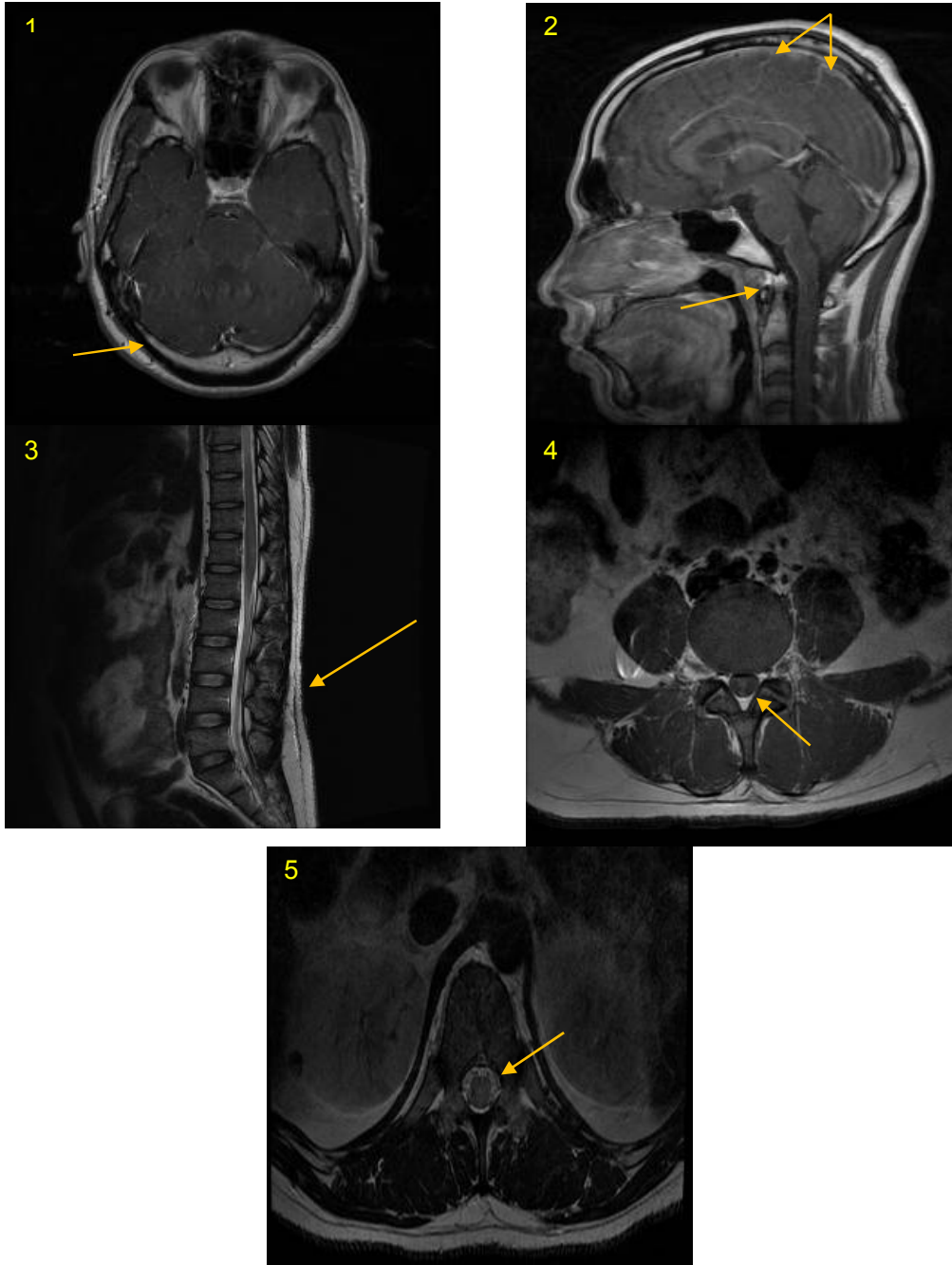
Here, we describe a 31-year-old previously healthy male with EBV-related acute meningitis with arachnoiditis.

2. CASE REPORT

A 31 years old Bangladesh male, with no known past medical history, presented with fever, headache, nausea and urinary retention for 1 month duration. He was initially admitted in a private hospital for the same symptoms and investigations done there included Lumbar puncture and MRI Brain. MRI brain was normal. CSF analysis there showed Lymphocytic pleocytosis. He was treated as a case of early bacterial meningitis, he received parenteral vancomycin and ceftriaxone for 10 days. Repeat Lumbar puncture was performed and it again showed significant lymphocytic pleocytosis of 96%. He was started on IV Acyclovir which he received for 2 days. He continued to have same symptoms of severe headaches, fevers, in addition he developed bilateral leg weakness and numbness 2 days prior to being transferred to our hospital. On March 8th 2015, he was referred to us as no improvement in his clinical condition. The patient denied any sick contacts, recent travel and any history of Tuberculosis (TB) or other chronic infections. He complained of low back pain along with urinary retention. On examination, patient was febrile (38.9), tachycardic, tachypnic, no photophobia or neck stiffness. On neurological exam, motor strength of bilateral lower extremities was 3/5 and for bilateral upper extremities was 4/5. Significant blood tests results were: WBC=12.4*10⁹/L with left shift, ALT 77 IU/L, Na 132 mmol/L. Chest x-ray showed Band atelectasis in the left mid zone. CSF analysis showed 540*10⁶/L Nucleated cells with 93% Lymphocytes, 71*10⁶/L Red blood cells, protein of 193 mg% and glucose of 2.72 mmol/L. The patient was started immediately on intravenous ceftriaxone, vancomycin and acyclovir. Ceftriaxone and vancomycin were stopped next day; as meningitis was unlikely bacterial. CSF cultures (bacterial and fungal) were negative. CSF was positive for EBV PCR. MDX PCR of HSV DNA, CMV DNA, enterovirus RNA and *Mycobacterium tuberculosis* was not detected. HIV Ag/Ab, Screening for brucella, salmonella and syphilis were negative as well. EBV titers in the blood turned out to be 250,000 copies/mL. Computed Tomography (CT) brain was unremarkable. MRI brain and spine showed few punctate foci of hyperintensity on T2 and

FLAIR in bilateral basal ganglia thalamic region which on sagittal views represents dilated Virchow robin spaces. Post contrast, smooth meningeal enhancement seen in bilateral cerebral hemisphere along the sulci and basal

cisterns. Diffuse dural enhancement involving cauda equina, conus medullaris and filum terminal, consistent with arachnoiditis. Myelopathic signal changes and edema of the conus medullaris opposite T12 [Images1-5].



Images 1-5. Smooth meningeal enhancement seen in bilateral cerebral hemisphere along the sulci and basal cisterns (images 1-2). Diffuse dural enhancement involving cauda equina, conus medullaris and filum terminal, consistent with arachnoiditis. Myelopathic signal changes and edema of the conus medullaris opposite T12

US KUB ruled out obstruction. The patient was started on IV pulse dose steroids (intravenous (IV) Hydrocortisone) which he received for 5 days. A repeat lumbar puncture after 7 days (showed similar results as the initial Lumbar tap). During the hospital stay, patient's symptoms gradually improved, headaches resolved completely. He however continued to have urinary retention and failed voiding trials multiple times and this required to keep him with the indwelling foley's catheter. The weakness of the arms completely resolved; however leg weakness took longer time to resolve with help of regular physiotherapy. Liver function returned to normal. Based on the MRI findings, CSF analysis and presence of hyponatremia, the patient was managed as a case of EBV meningitis with arachnoiditis. The patient was treated with 2 weeks course of IV acyclovir 700 mg q8h (12.7 mg/kg), steroids were tapered over 2months period. EBV titers in the blood reduced from 250,000 to 12,250 Copies/ml down to undetected upon completion of therapy. He was discharged after 44 days. He was able to walk independently; but still had persistent urinary retention for which he received education about In-and-Out catheterization. We lost follow up of the patient because he traveled back to his home country. He was advised to follow up there with infectious diseases, neurology and urology subspecialties and was educated about his medications.

3. DISCUSSION

EBV causes a variety of neurological presentations including aseptic meningitis, encephalomyelitis and neuritis. The EBV neuropathies present with ophthalmoplegia, lumbosacral plexopathy, and sensory or autonomic neuropathy [10]. Such association has been suggested by the presence of positive serum heterophile antibody titer and EBV DNA, antibody or both in CSF [11]. The exact pathogenesis of EBV-associated neurologic complications is not completely understood. One of the hypothesis is that immunocytotoxicity is caused by infiltration of catatonic CD8+ cells into the neural tissue. Alternatively, deposition of circulating antigen-antibody complexes is suggested as a cause of endothelial changes resulting in tissue damage [12]. A comprehensive analysis of patients with EBV associated meningoencephalitis has shown that using neuroimaging studies with CT and MRI showed abnormal radiologic findings (especially an increased signal or less commonly, linear

enhancement and multiple small enhancing nodules in the spinal cord and lumbosacral roots) in up to 60% of the patients; 70% made a full recovery, 20% had neurologic sequelae and 10% died [13]. In another analysis of four patients with EBV meningoencephalomyelorradiculitis [10], the CSF contained mononuclear pleocytosis with elevated protein and normal glucose; in two patients, MRI scans revealed an increased signal in the spinal cord and lumbosacral roots, but no brain swelling or focal changes. Our patient had the clinical features and laboratory results indicative of acute EBV meningoencephalitis from primary infection. Despite the lack of significant brain edema or focal changes on MRI of most patients with EBV encephalomyelorradiculopathy, serious residual neurological deficit was present in patients with documented EBV encephalitis [14]. Our patient sustained urinary retention. Unfortunately, there is no definitive treatment for EBV associated CNS infection. Steroids and immunoglobulins have been used, but their effects on disease progression are unknown [15]. Our patient was immunocompetent and had no known risk factors for EBV infection. He recovered from the acute infection. We attribute this success to several elements: first is the use of systemic antiviral therapy and pulse doses of steroids. Second is the comprehensive and multidisciplinary management.

4. CONCLUSION

EBV meningoencephalitis should always be considered even in patients who are young with no past medical history. EBV can cause a wide spectrum of manifestations, from tumors, immunodeficiency states to severe CNS infections. The mechanism by which EBV produces neurological disease is unknown; more correlative pathological, virological and immunological studies are needed. Since EBV has a unique presentation, using CSF studies and MRI scans are useful for diagnosis.

CONSENT

All authors declare that written informed consent was obtained from the patient (or other approved parties) for publication of this case report.

ETHICAL APPROVAL

All authors hereby declare that this case study has been examined and approved by the appropriate ethics committee and have therefore

been performed in accordance with the ethical standards laid down in the 1964 Declaration of Helsinki.

COMPETING INTERESTS

Authors have declared that no competing interests exist.

REFERENCES

1. Cohen JL. Epstein-Barr virus infection. [Review]. *New Engl J Med.* 2000;343: 481–92.
2. Dreyfus DH. Autoimmune disease: A role for new anti-viral therapies? *Autoimmun Rev.* 2011;11(2):88-97. DOI: 10.1016/j.autrev.2011.08.005. (Epub 2011 Aug 18)
3. Gautier-Smith PC. Neurological complications of glandular fever (infectious mononucleosis). *Brain.* 1965;88:323–34.
4. Silverstein A, Steinberg G, Nathanson M. Nervous system involvement in infectious mononucleosis. The heralding and/or major manifestation. *Arch Neurol.* 1972; 26:353–8.
5. MacMahon EM, Glass JD, Hayward SD, Mann RB, Becker PS, Charache P, et al. Epstein-Barr virus in AIDS-related primary central nervous system lymphoma. *Lancet.* 1991;338:969–73.
6. Bennett JL, Mahalingam R, Wellish MC, Gilden DH. Epstein-Barr virus-associated acute autonomic neuropathy. *Ann Neurol.* 1996;40:453–5.
7. Feinberg WM, Zonis J, Minnich LL. Epstein-Barr virus-associated myelopathy in an adult. *Arch Neurol.* 1984;41:454–5.
8. Paskavitz JF, Anderson CA, Filley CM, Kleinschmidt-DeMasters BK, Tyler KL. Acute arcuate fiber demyelinating encephalopathy following Epstein-Barr virus infection. *Ann Neurol.* 1995;38:127–31.
9. Casas I, Pozo F, Trallero G, Echevarría JM, Tenorio A. Viral diagnosis of neurological infection by RT multiplex PCR: A search for entero- and herpes viruses in a prospective study. *J Med Virol.* 1999;57:145–51.
10. Majid A, et al. Epstein-Barr virus myeloradiculitis and encephalomyelodulitis. *Brain.* 2002; 125:159-165.
11. Bennett JL, et al. Epstein-Barr virus-associated acute autonomic neuropathy. *Ann Neurol.* 1996;40:453-455.
12. Dennis Nyuk Fung Lim. EBV meningoencephalitis and rheumatoid arthritis. *Grand Rounds.* 2009;9:49–53. DOI: 10.1102/1470-5206.2009.0014/.
13. Abu-Kasim K, Palm L, Maly P, Sundgren PC. The neuroanatomic localization of Epstein-Barr virus encephalitis may be a predictive factor for its clinical outcome: A case report and review of 100 cases in 28 reports. *J Child Neurol.* 2009;24:720–6. DOI:10.1177/0883073808327842. PMID:19151367.
14. Paskavitz JF, Anderson CA, Filley CM, Kleinschmidt-DeMasters BK, Tyler KL. Acute arcuate fiber demyelinating encephalopathy following Epstein-Barr virus infection. *Ann Neurol.* 1995;38:127–31.
15. Bennett JL, Mahalingam R, Wellish MC, Gilden DH. Epstein-Barr virus-associated acute autonomic neuropathy. *Ann Neurol.* 1996;40:453–5.

© 2015 Albhaisi and Khan; This is an Open Access article distributed under the terms of the Creative Commons Attribution License (<http://creativecommons.org/licenses/by/4.0>), which permits unrestricted use, distribution, and reproduction in any medium, provided the original work is properly cited.

Peer-review history:

The peer review history for this paper can be accessed here:
<http://sciencedomain.org/review-history/10552>